

OCD Case Report

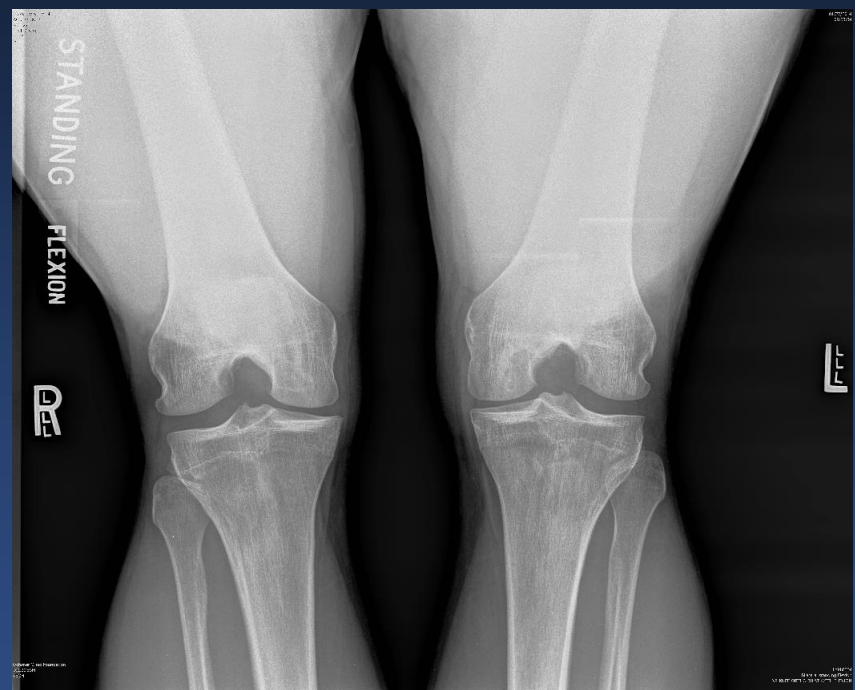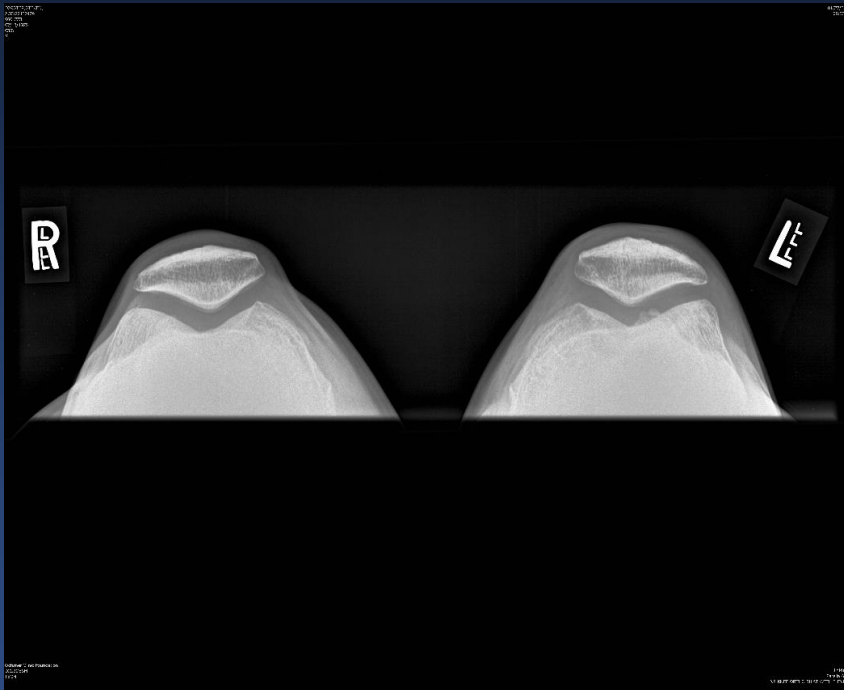Deryk Jones, MD
Head

Ochsner Sports Medicine Institute
Professor University of Queensland

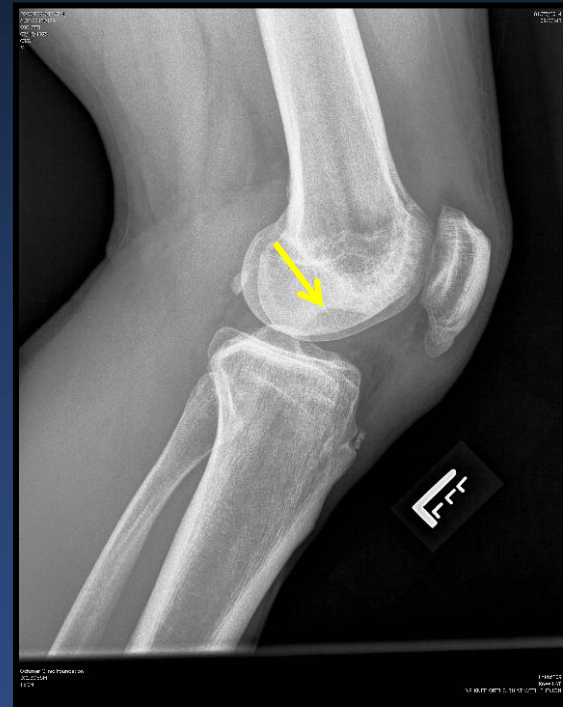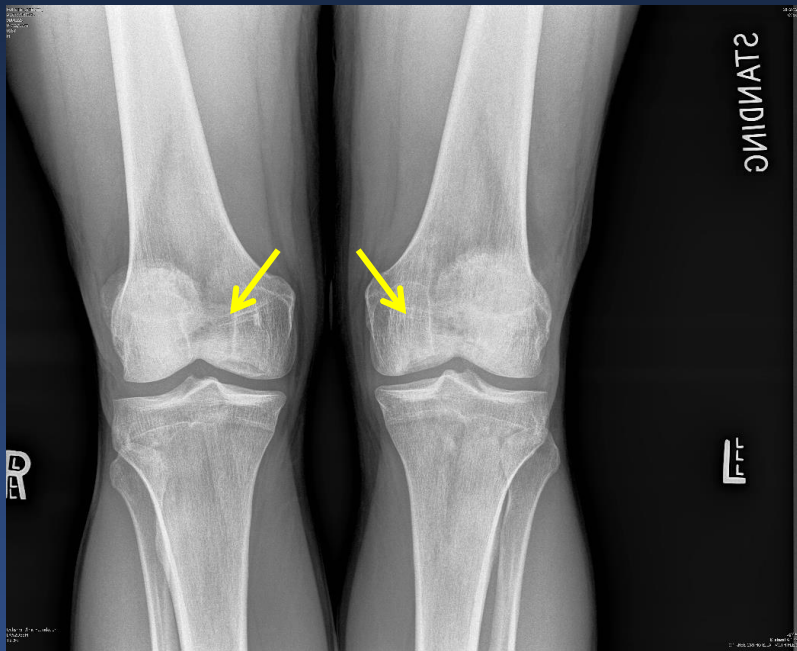
History

- 35 y.o. male – Distance Runner
- Knee pain 3-4 years
- Arthroscopic procedures:
 - # 1 – Debridement
 - #2 – ORIF OCD lesion (5/2013)
 - # 3 Screw removal + debridement “lesion too large for bone grafting”
- Referral for consultation

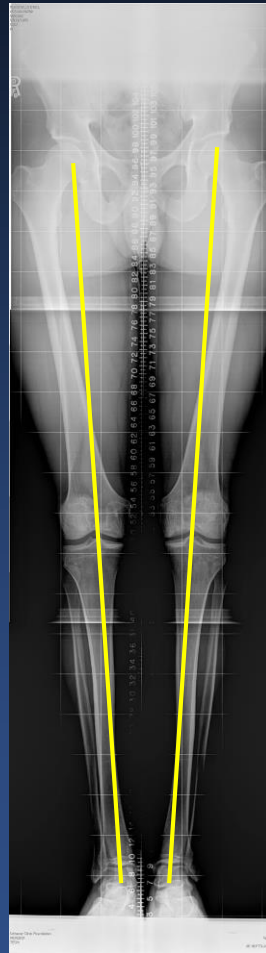
Preoperative Radiographs



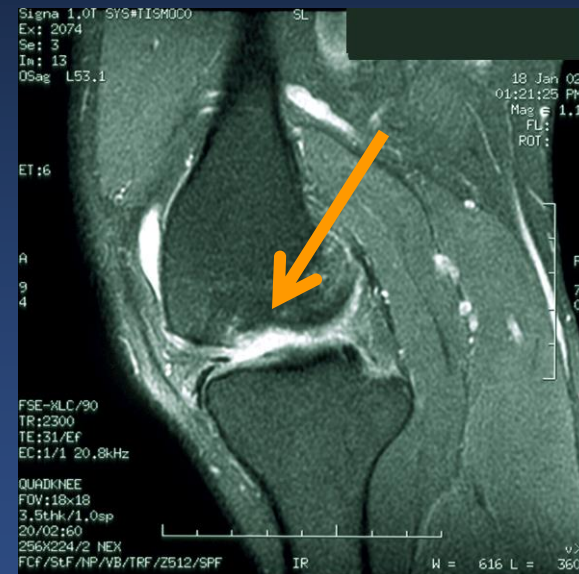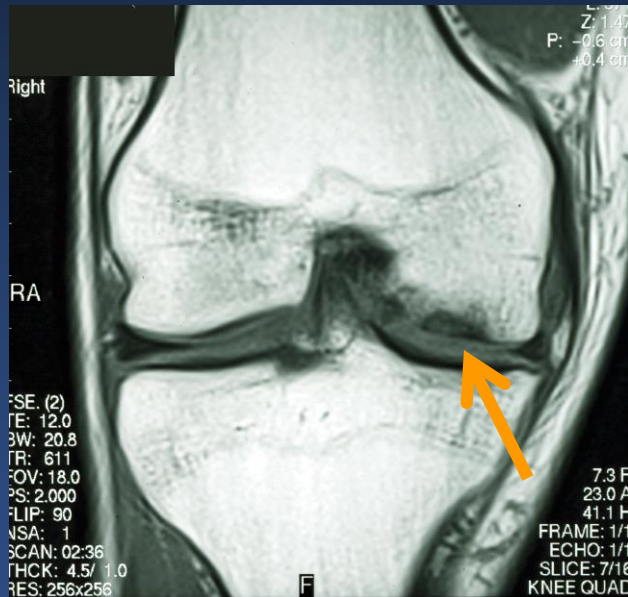
Radiographic Studies



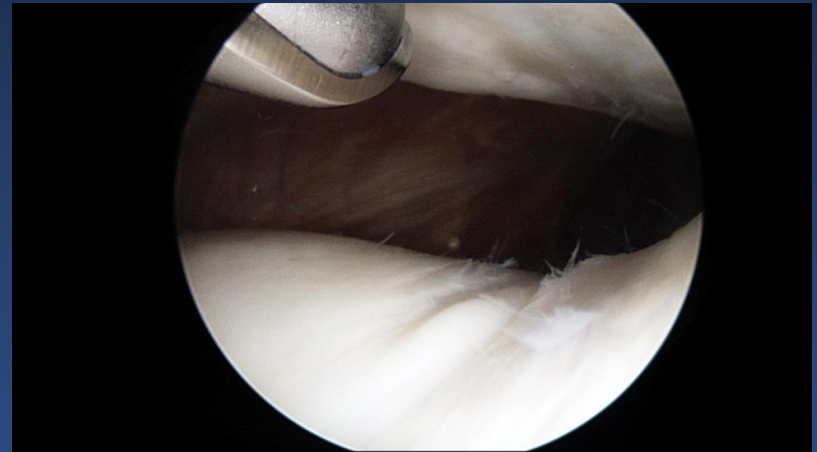
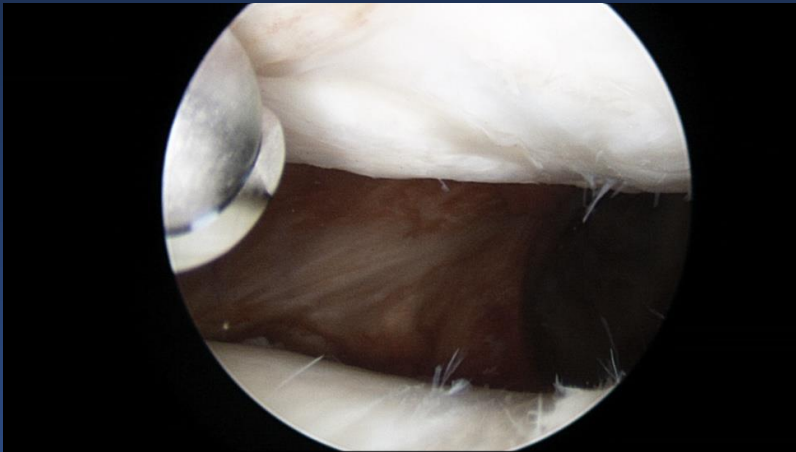
Long leg Radiographs Preoperative



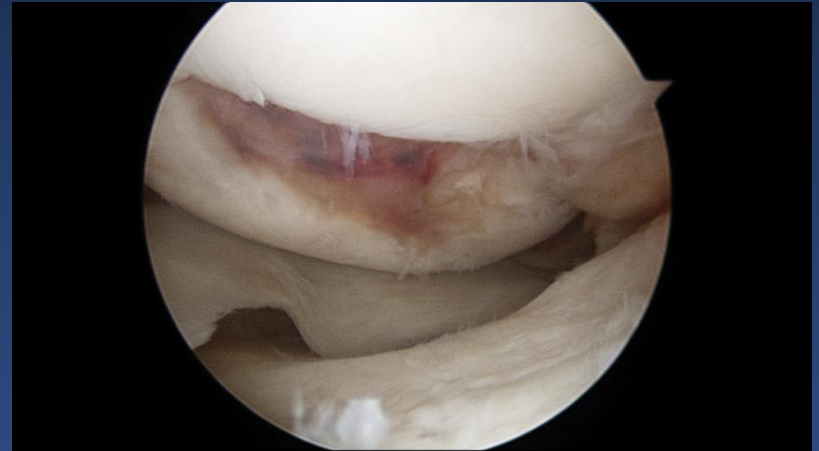
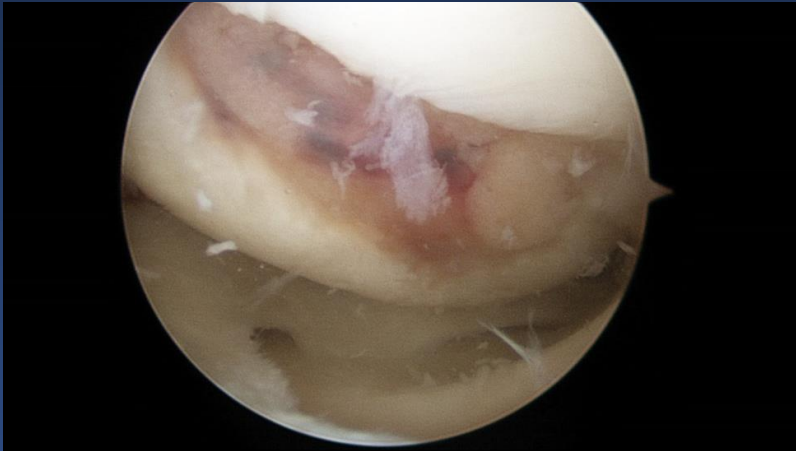Preoperative MRI



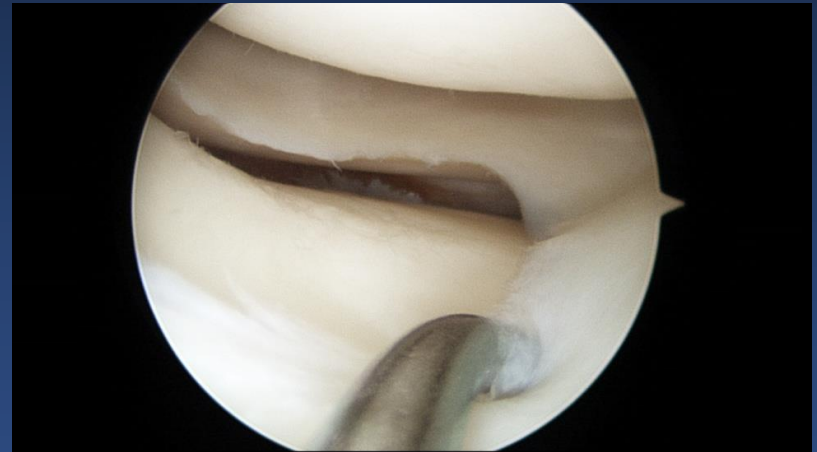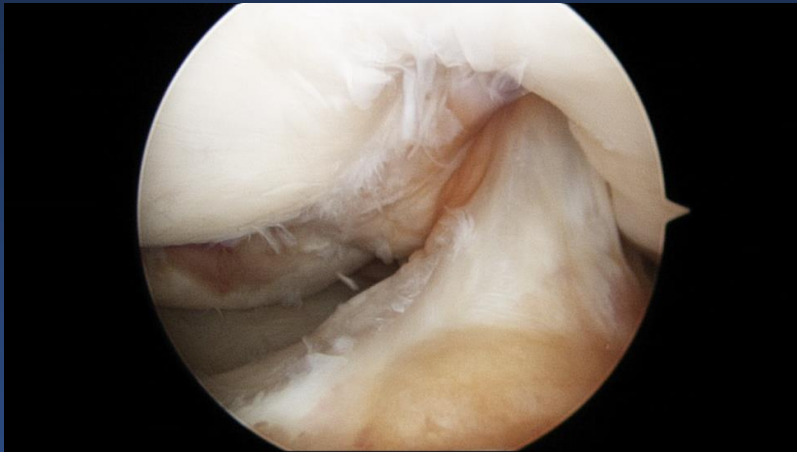
Arthroscopic View Patellofemoral Joint



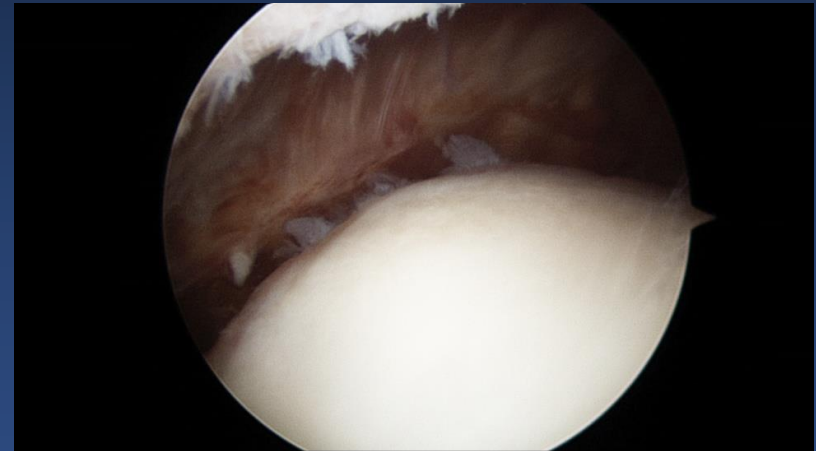
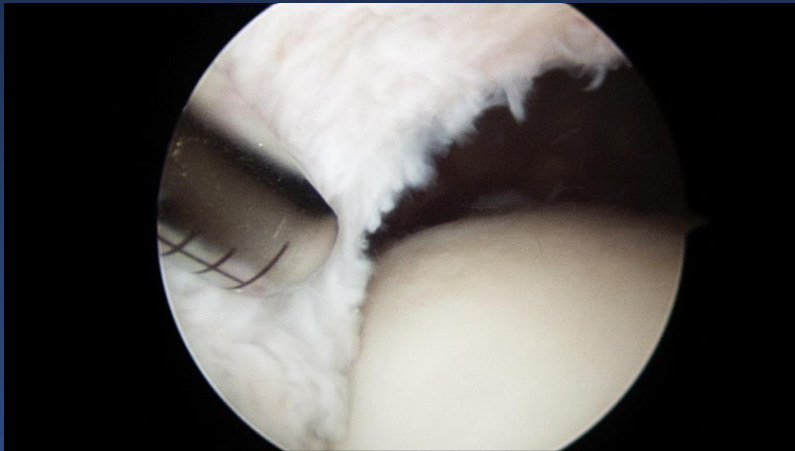
Arthroscopic View OCD lesion



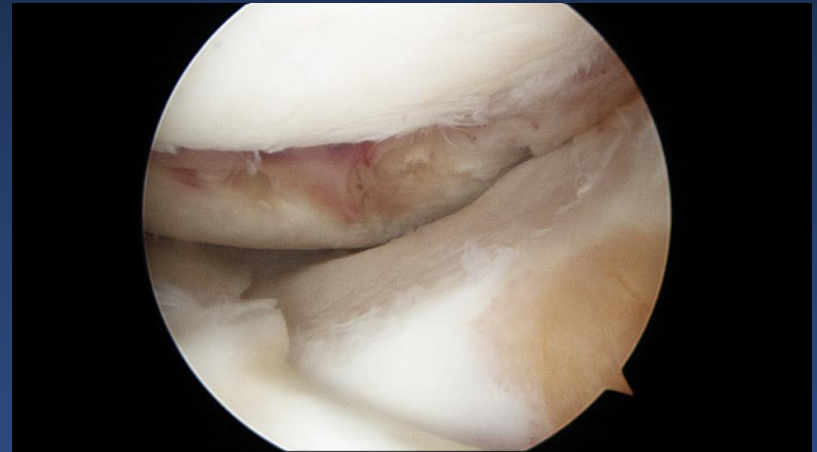
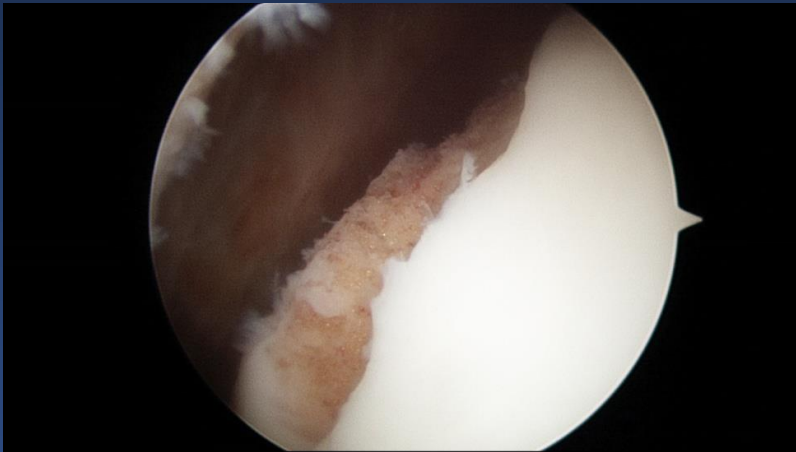Arthroscopic View OCD lesion



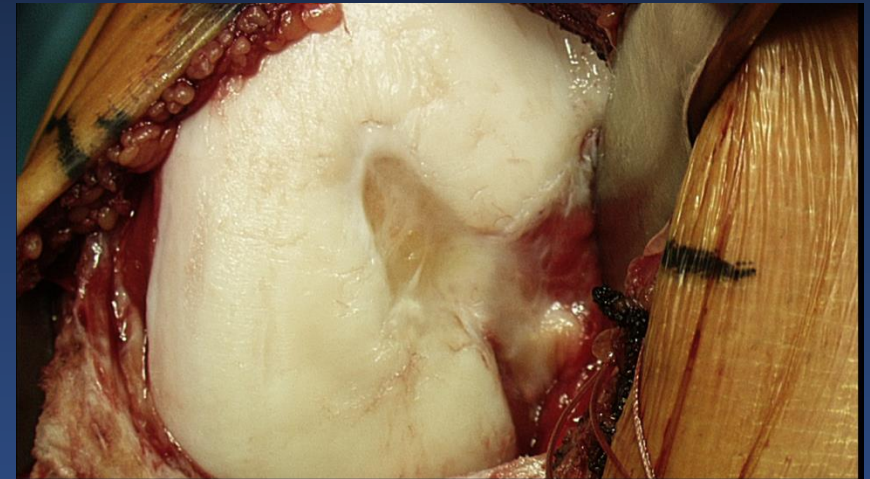
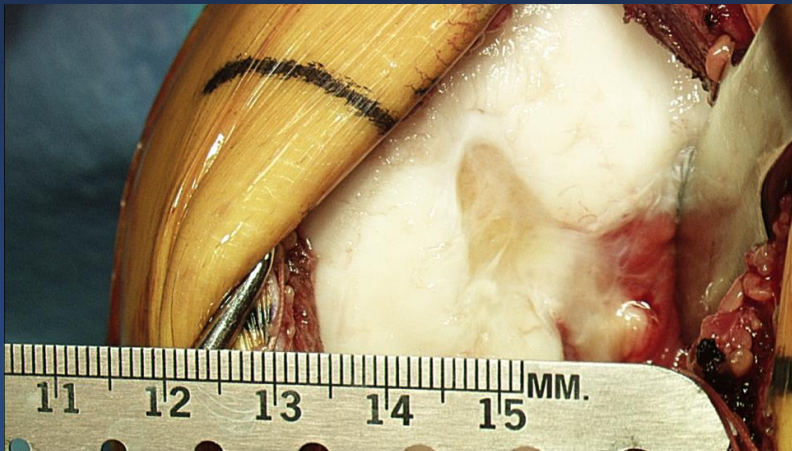Arthroscopic View OCD lesion



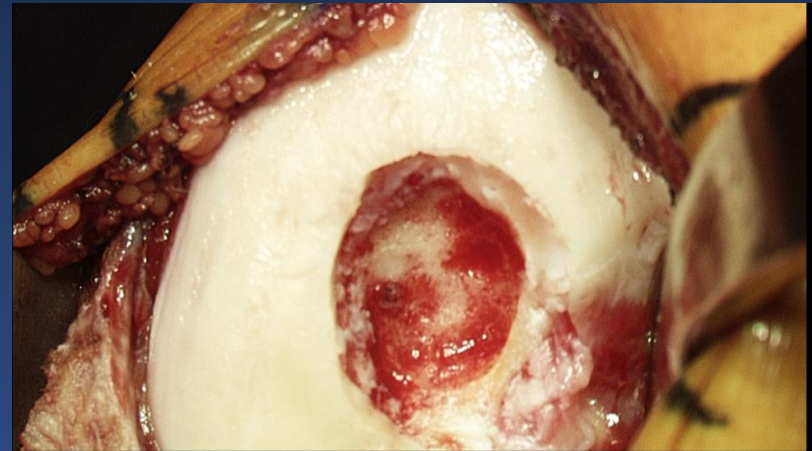
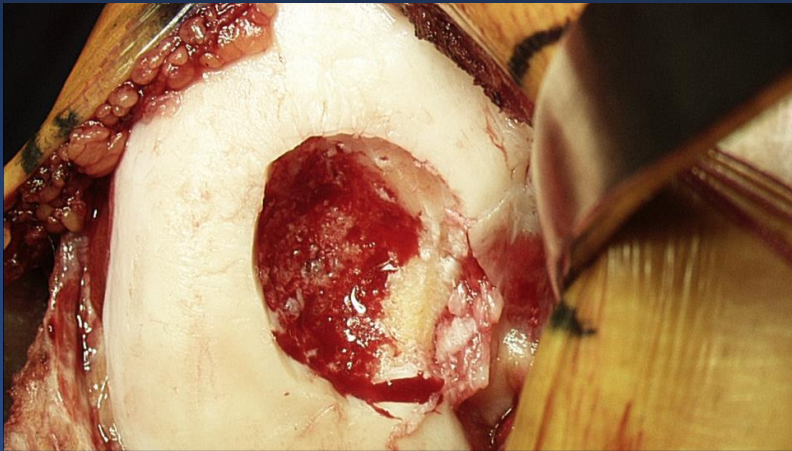
Arthroscopic View OCD lesion



Open View OCD Lesion



Open View OCD Lesion

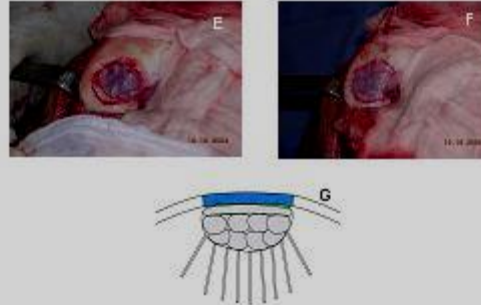


“Sandwich” Technique

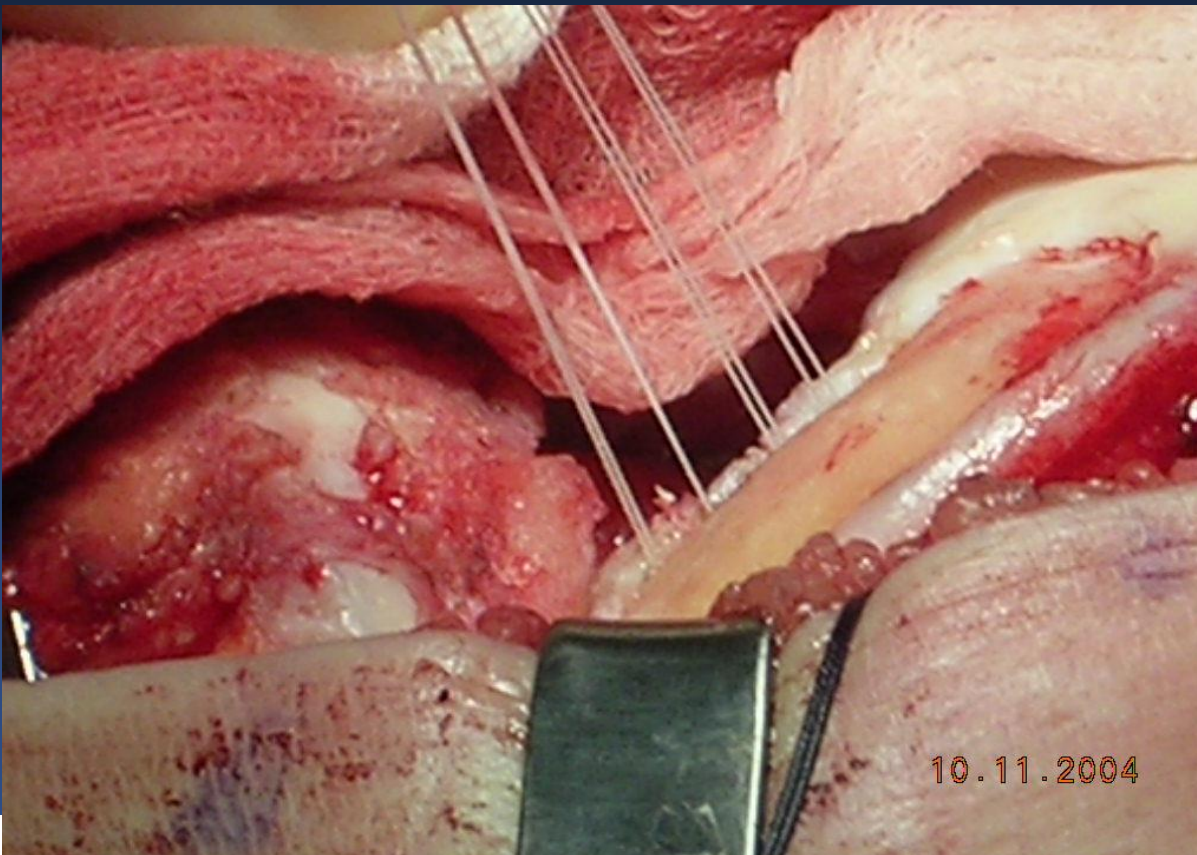
Inner Flap

Outer Flap

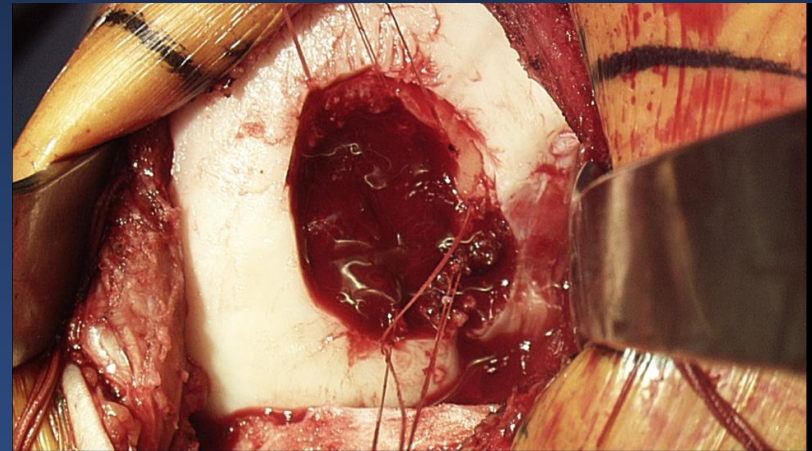
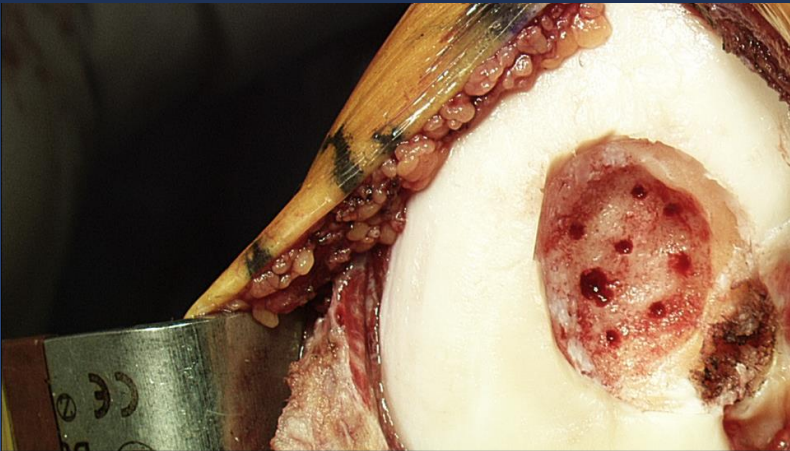
Figure 8



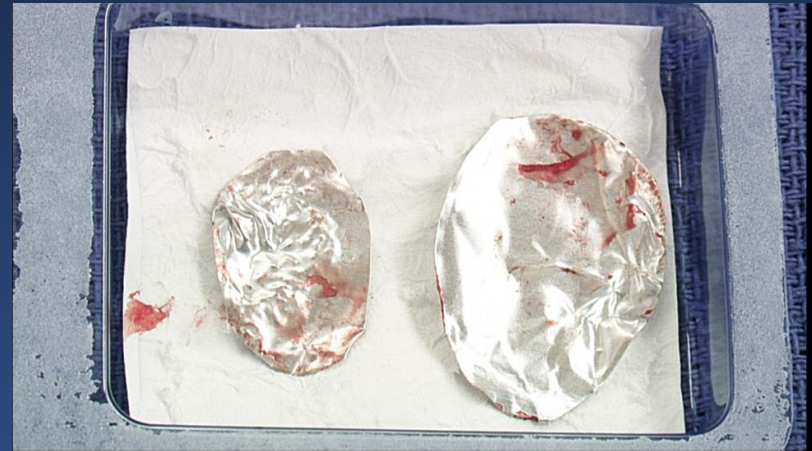
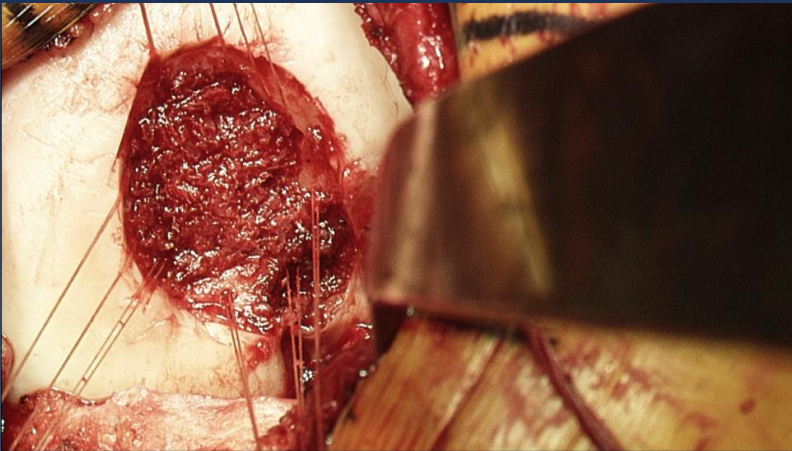
Poorly Contained Lesion – Anchor applied



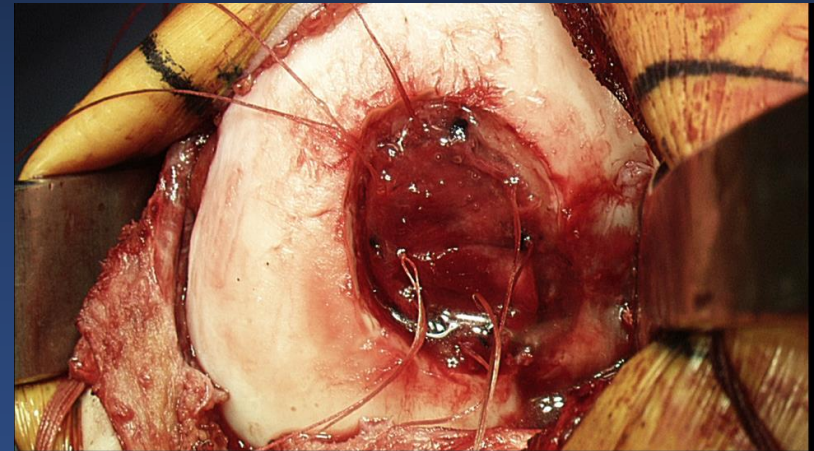
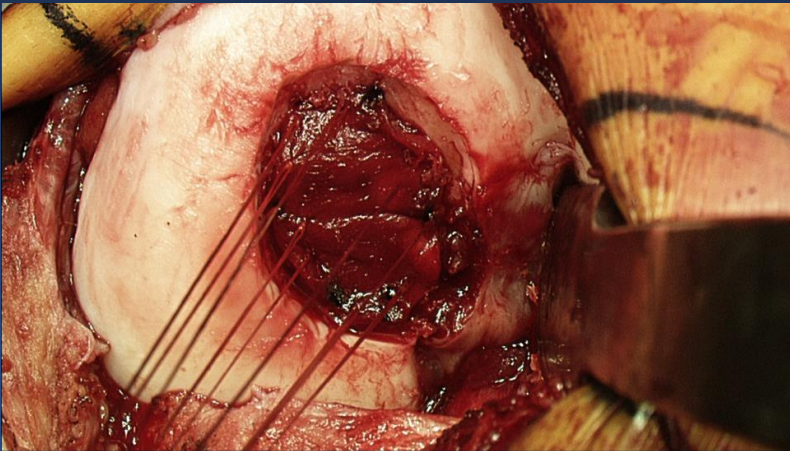
Open View OCD Lesion



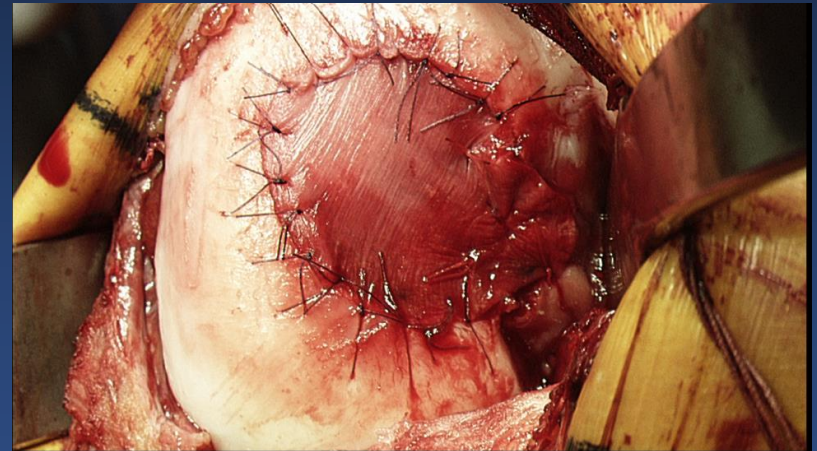
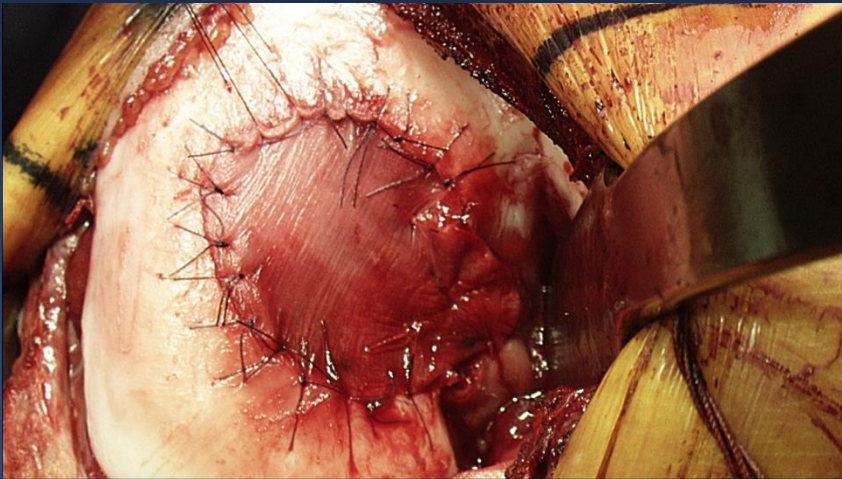
Bone grafting + Base Templating



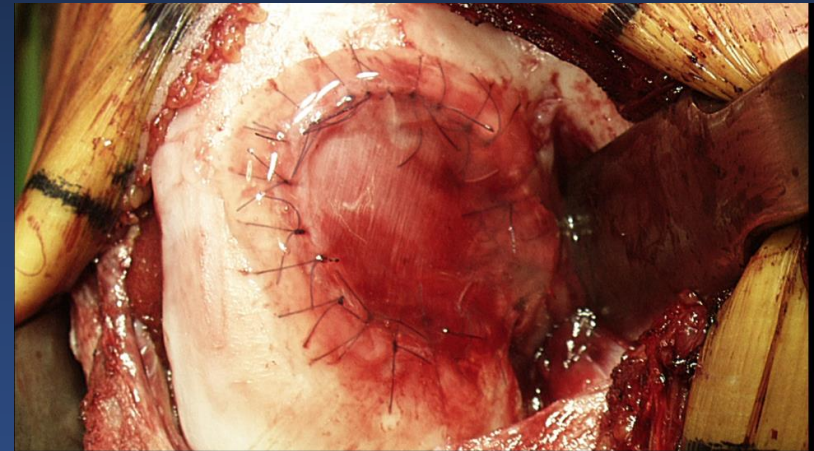
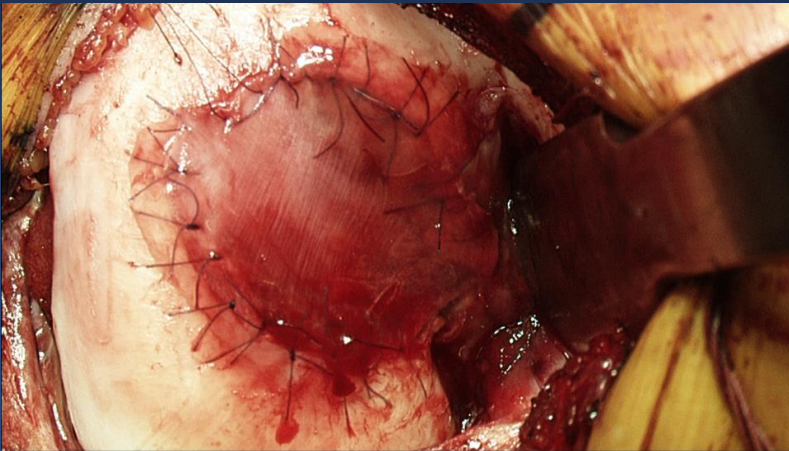
Inner Graft Cambium layer Facing up



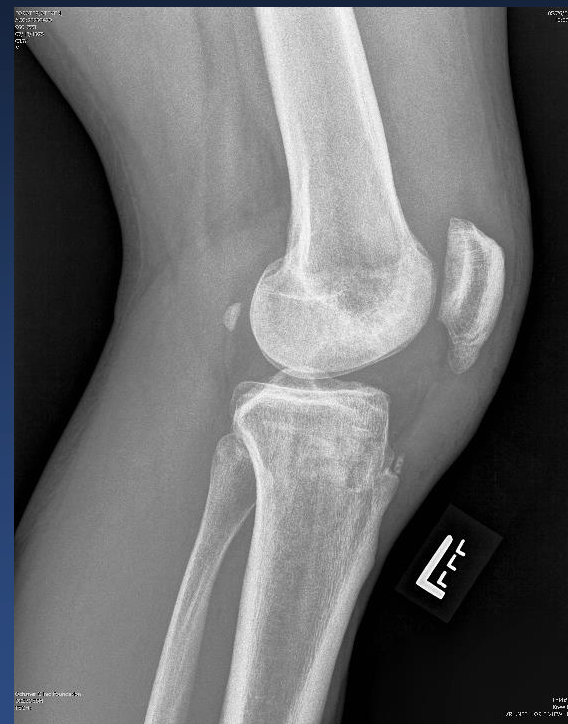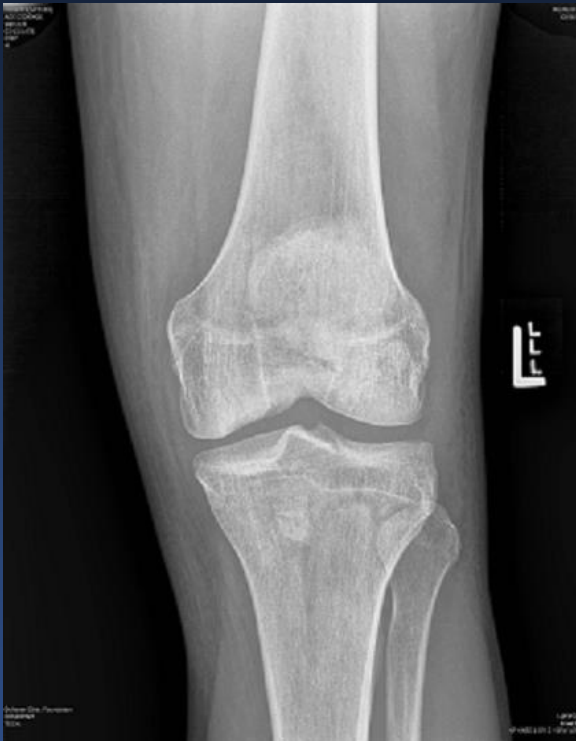Outer layer Cambium Layer facing down



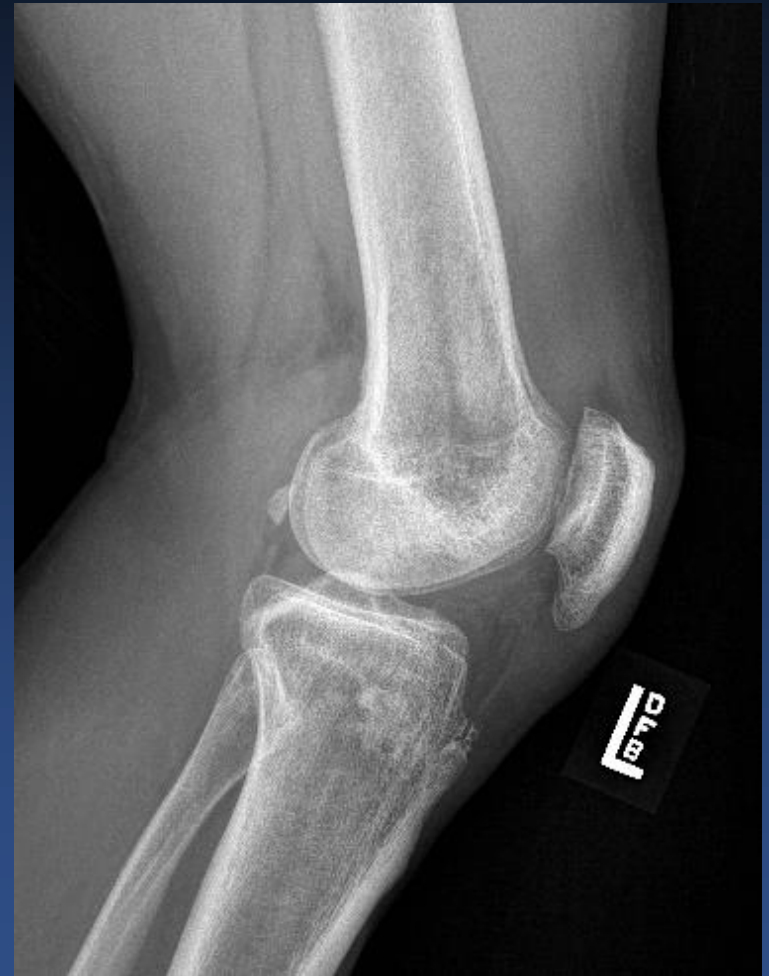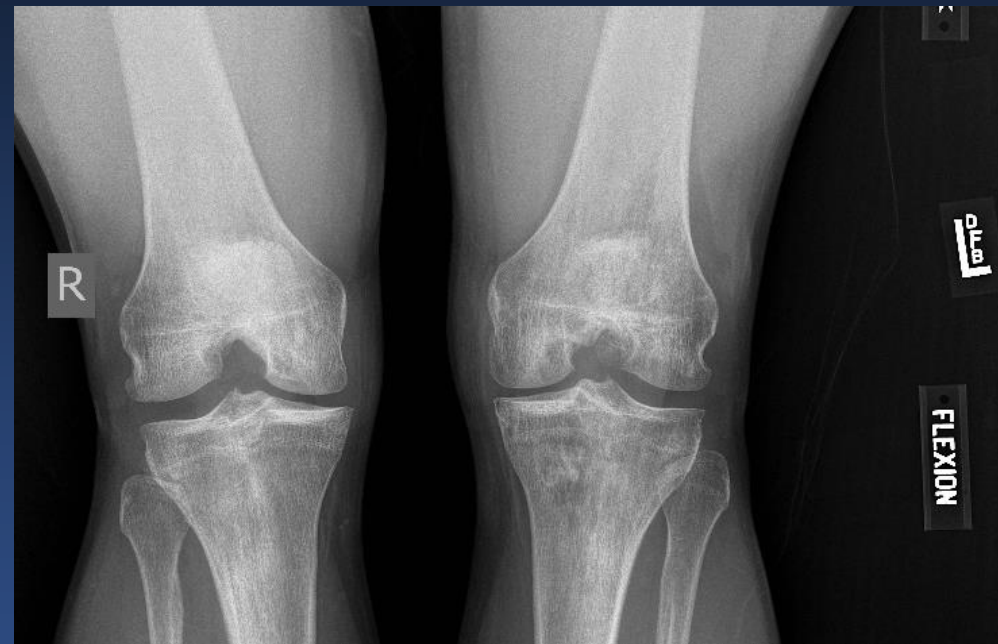Sealed Defect



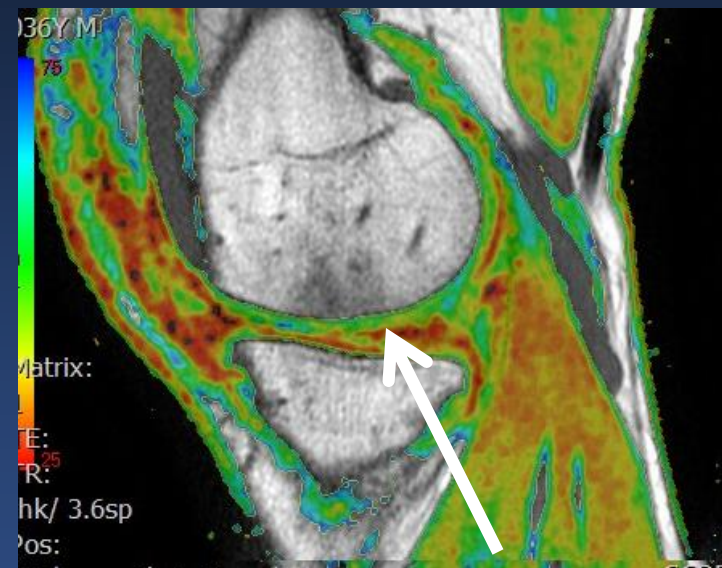
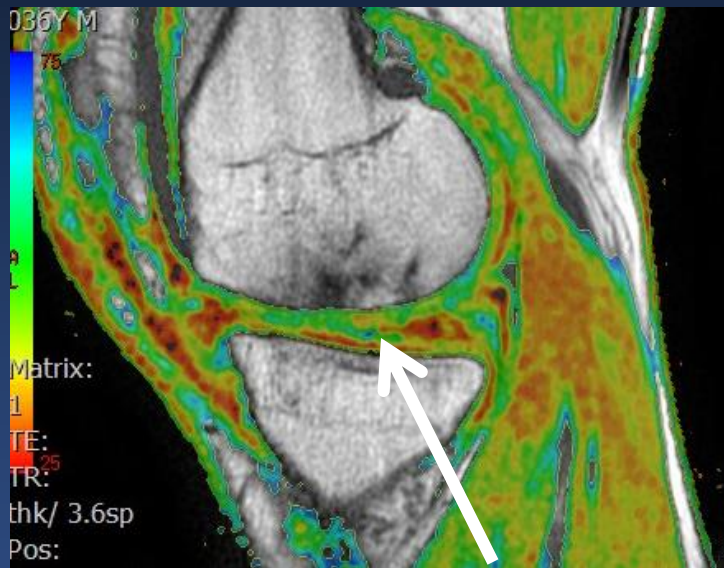
Postoperative Radiographs Immediate



Postoperative Standing Radiographs



T2 Mapping Postoperatively



Postoperative MRI Cartilage Specific Sequences

