

Autologous Chondrocyte Implantation Trochlear Lesion

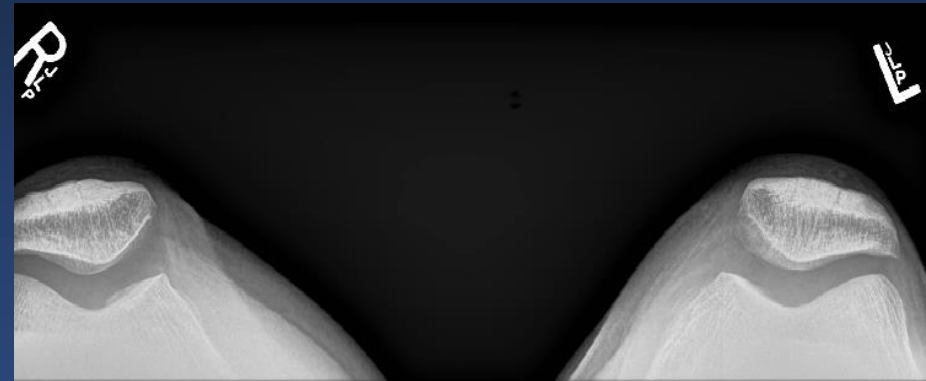
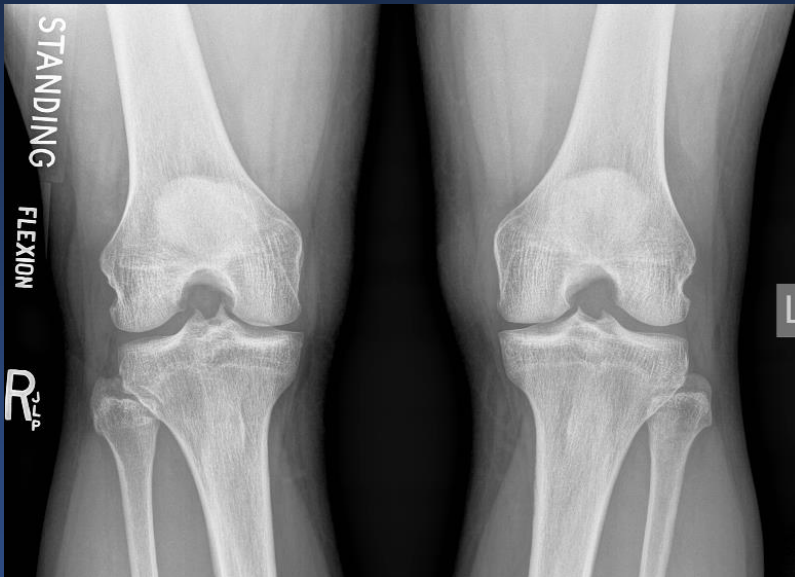Deryk Jones, MD
Section Head

Ochsner Sports Medicine Institute
Professor University of Queensland

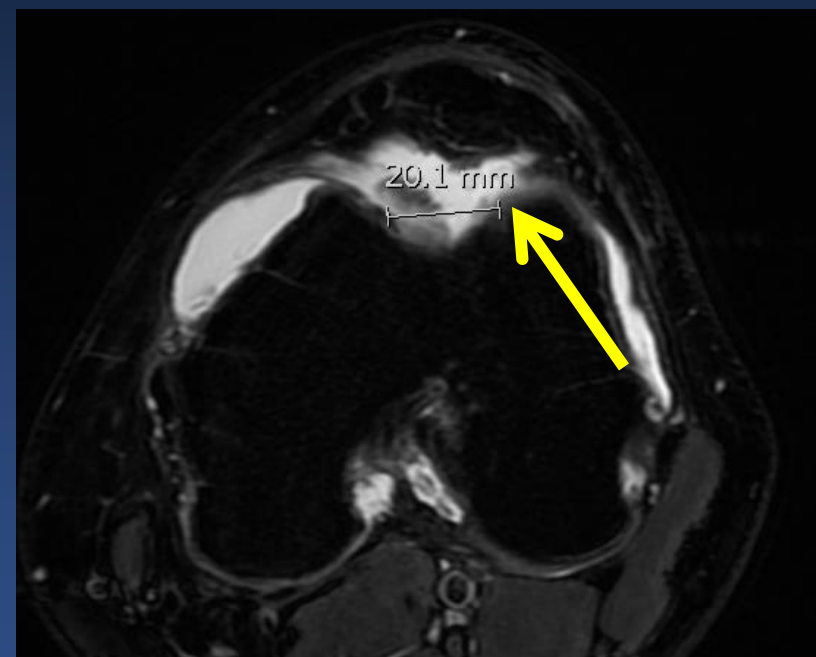
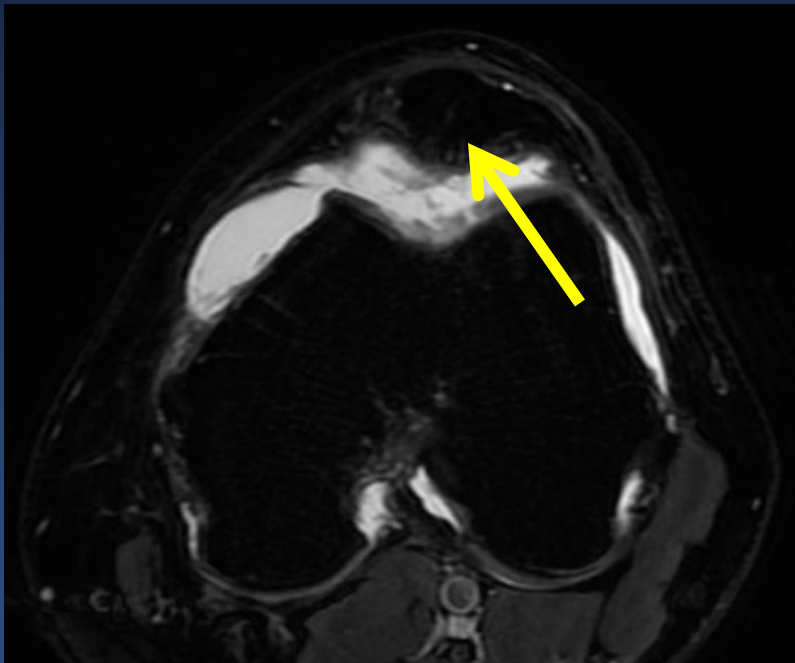
History

- 32 y.o. male
- 2002 Left knee weight lifting injury-
Squats
- Swelling – mechanical sx
 - MRI – outside “negative”
- 2010 – recurrent Swelling noted
 - MRI – Chondral Loss noted
- Recurrent activity related Swelling - +/-
relief with rest / NSAIDS

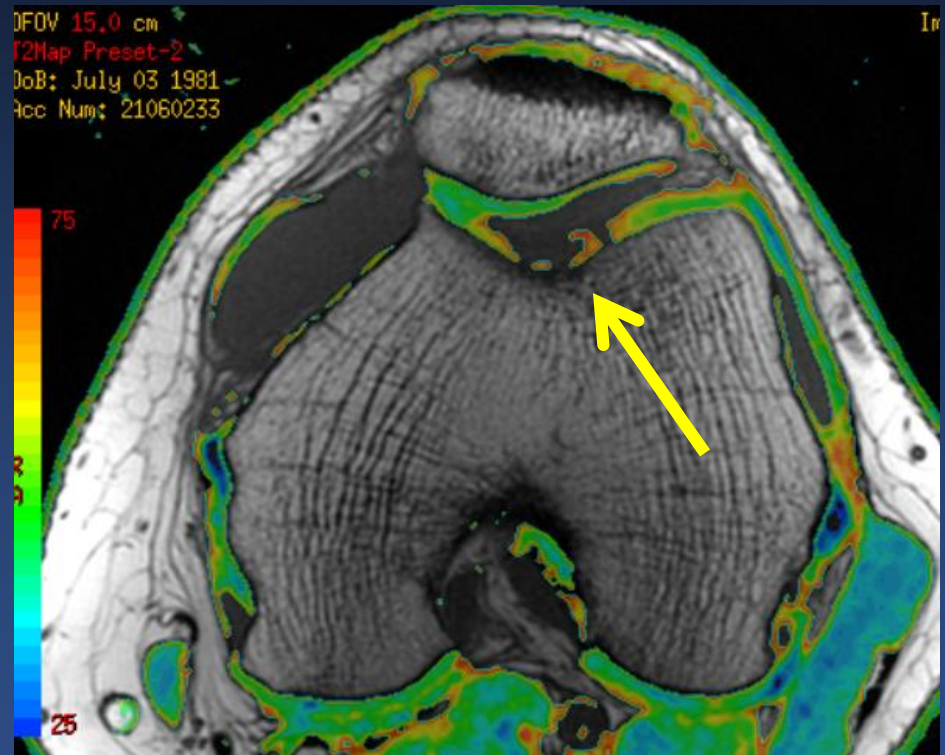
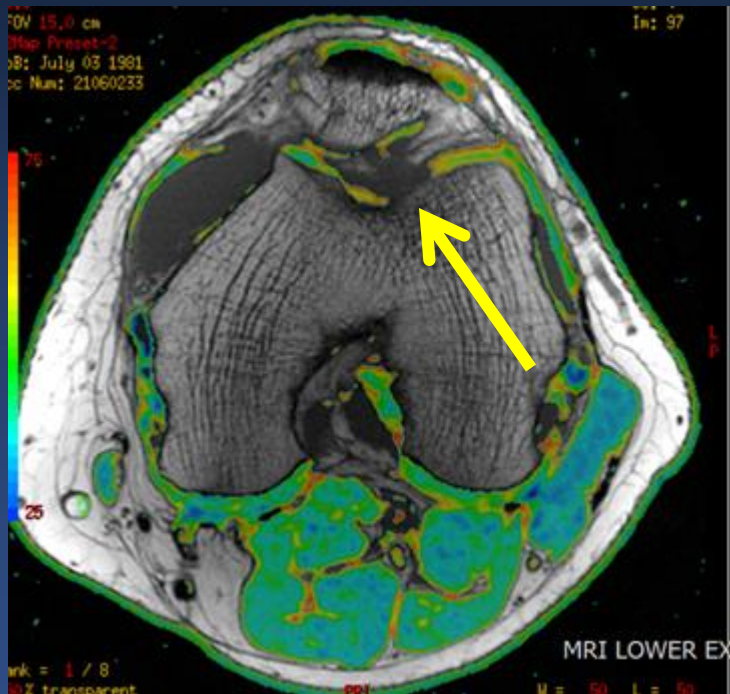
Preoperative Radiographs



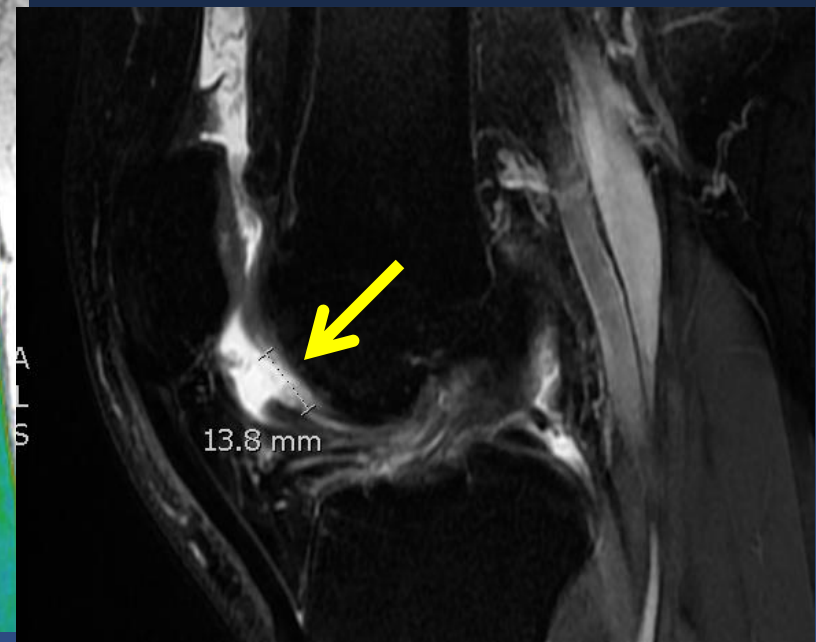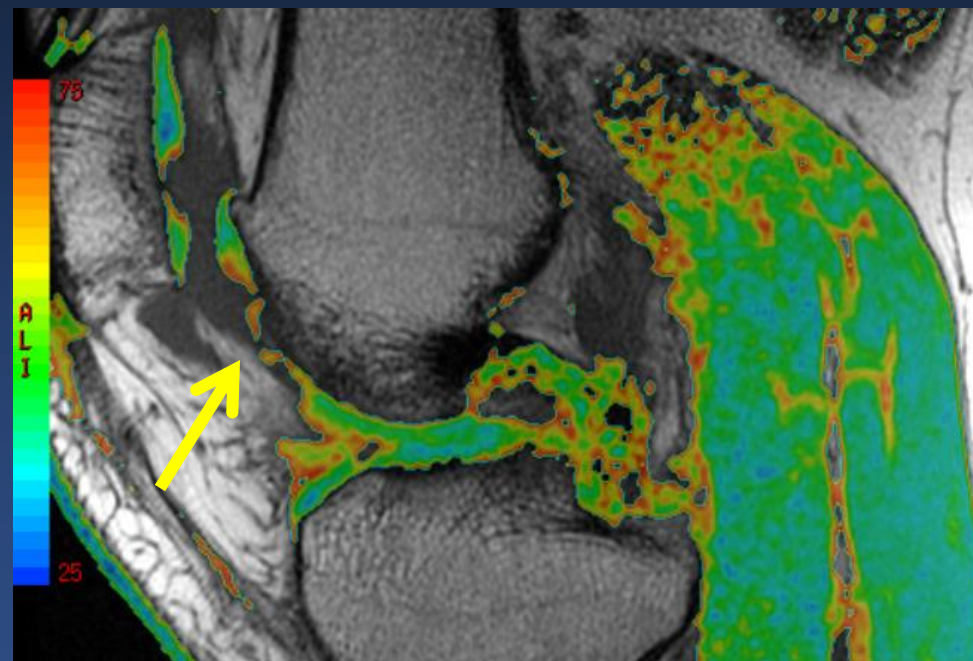
Axial MRI – Trochlear Defect



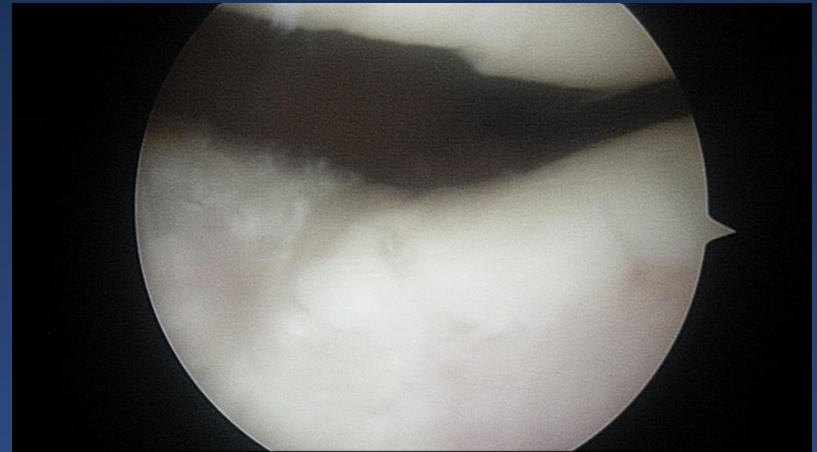
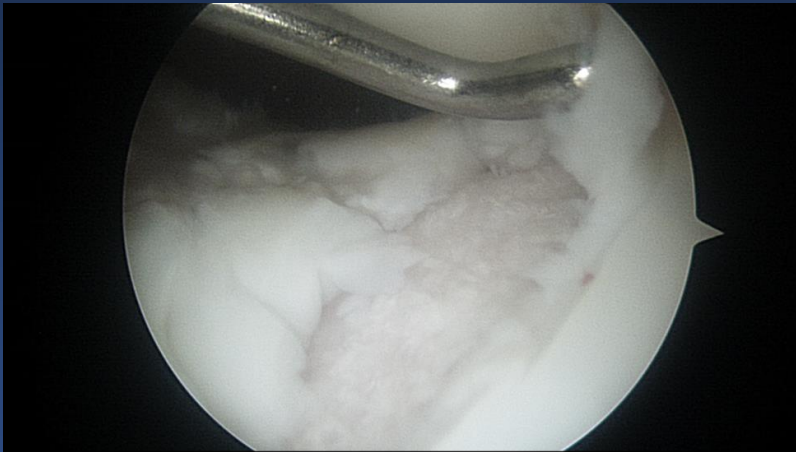Axial T2 MRI – Trochlear Defect



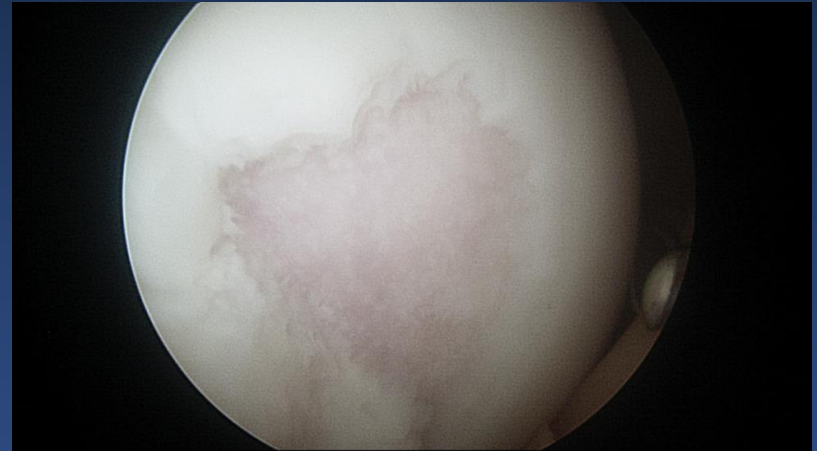
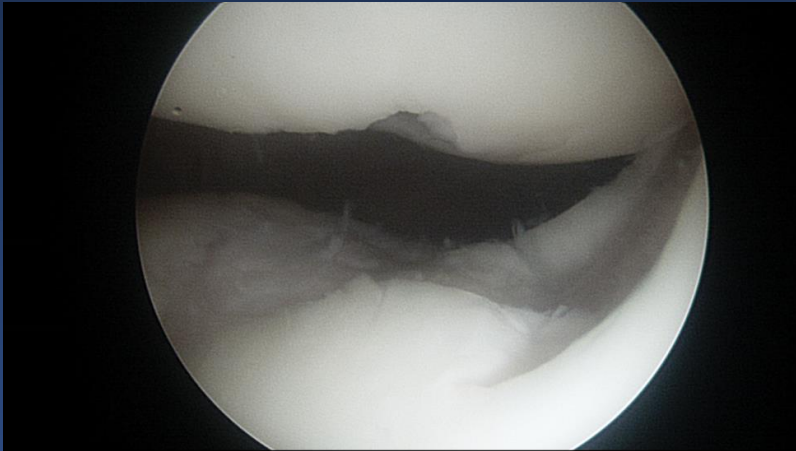
Sagittal View Trochlear Lesion



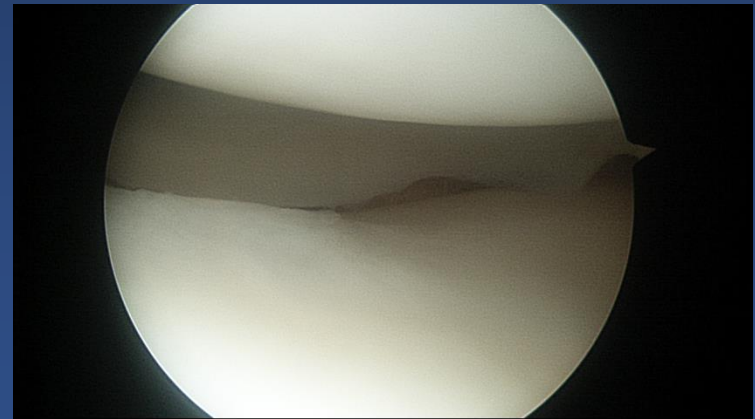
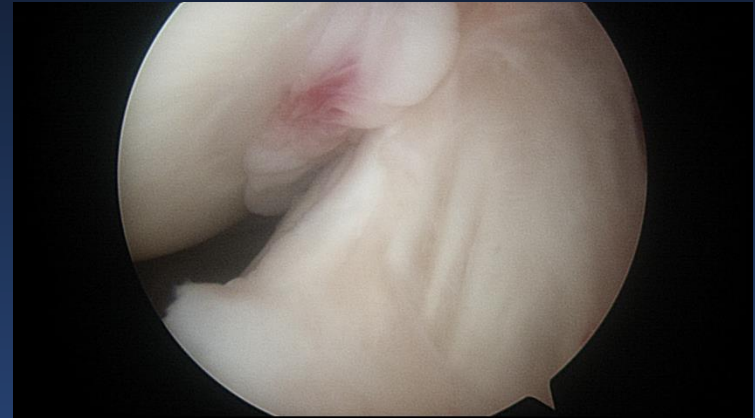
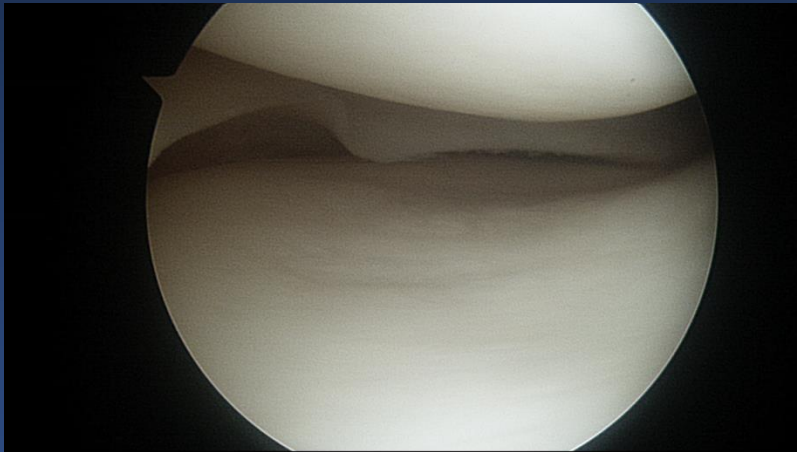
Arthroscopic View Trochlear Lesion



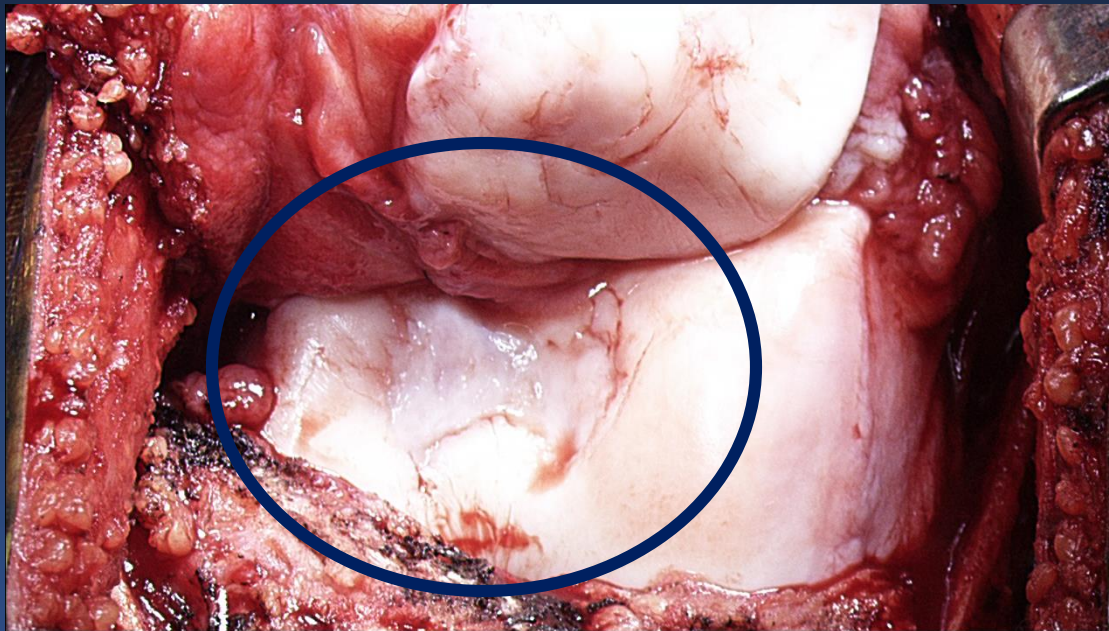
Arthroscopic Pictures- Trochlear Lesion



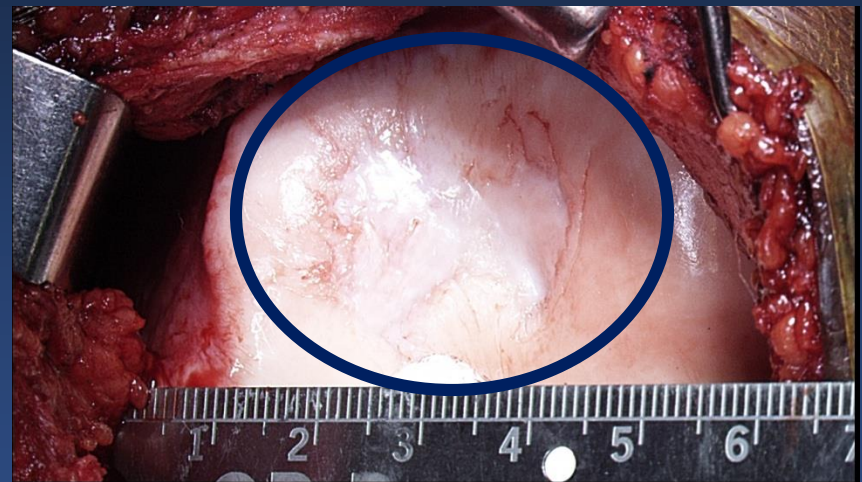
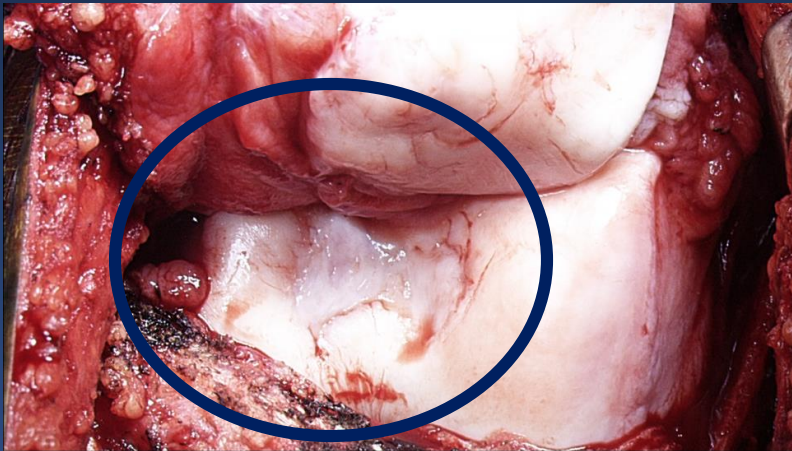
Arthroscopic Pictures



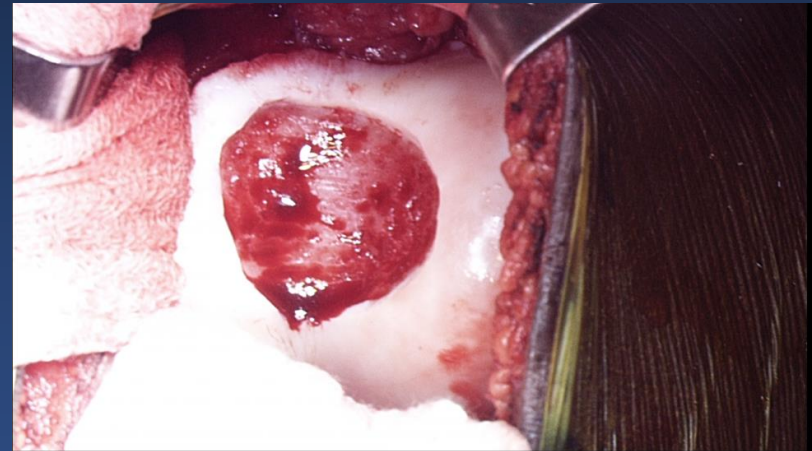
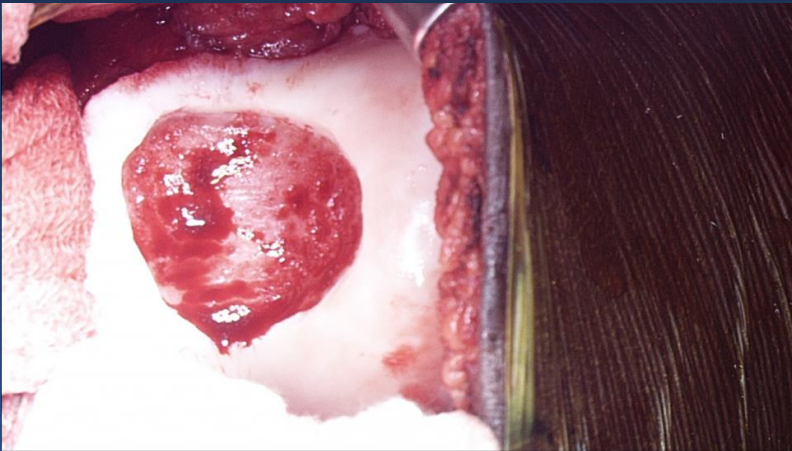
Trochlear lesion



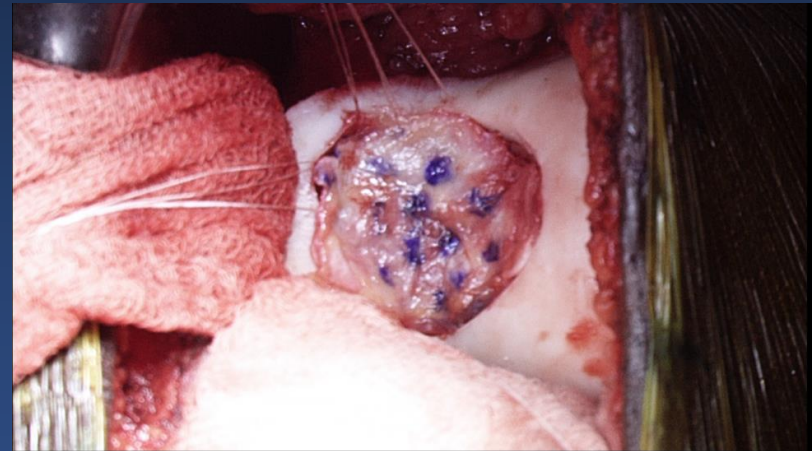
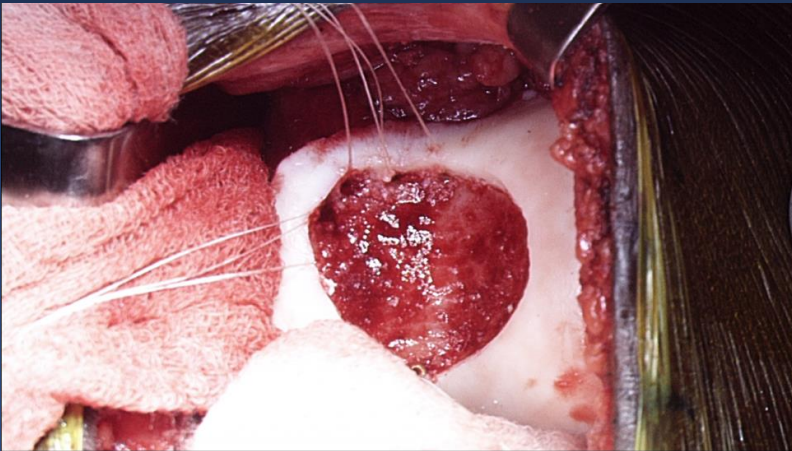
Intraoperative measurements



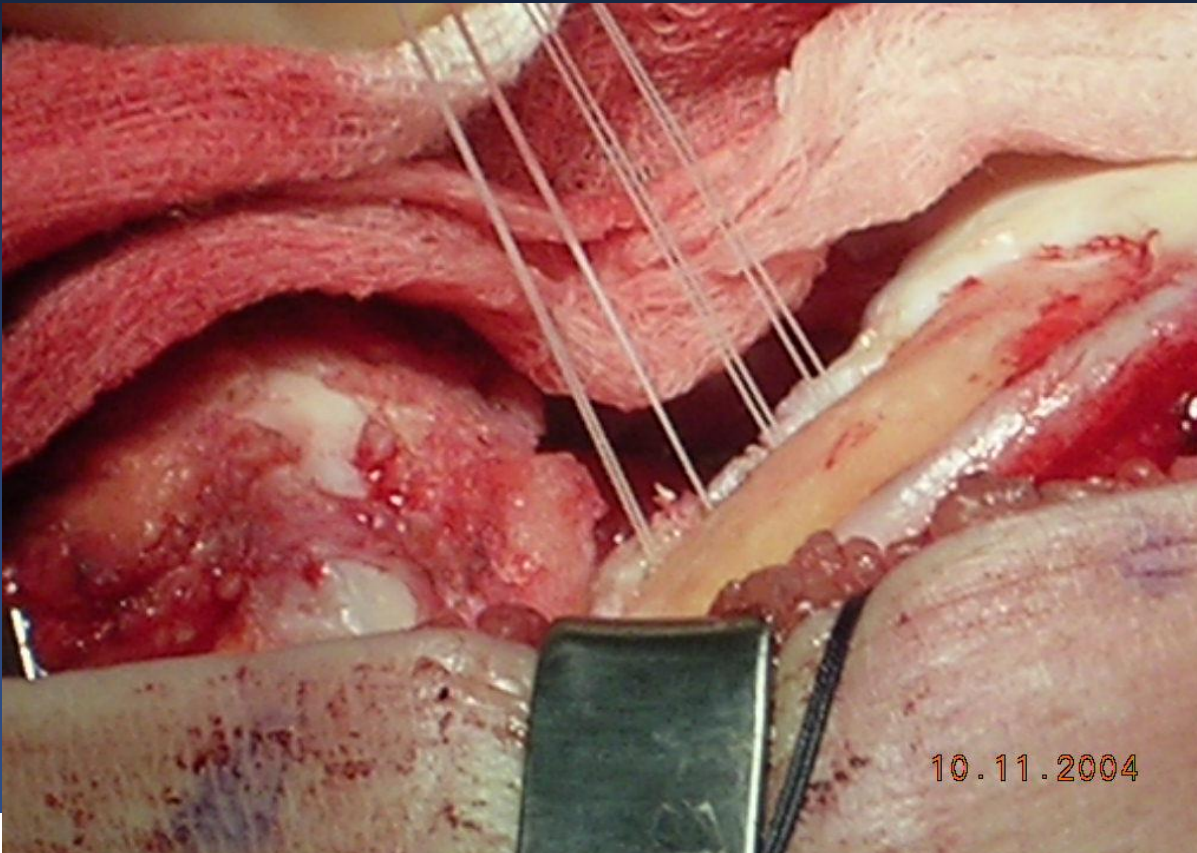
Preparation defect



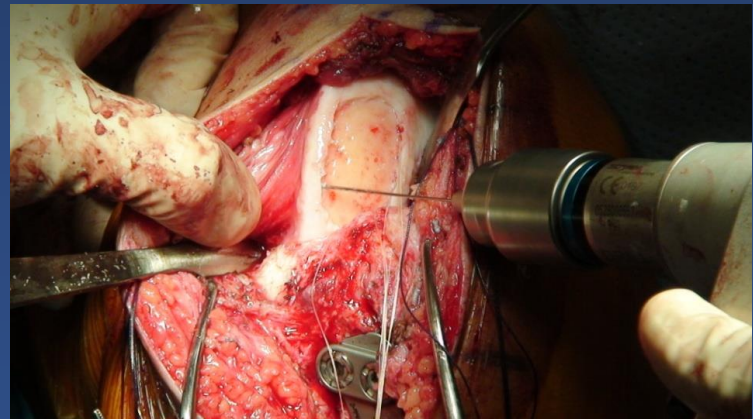
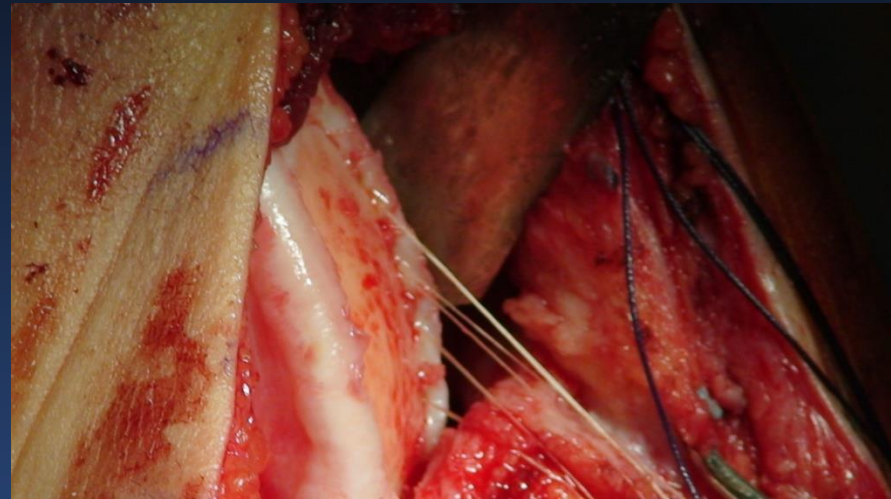
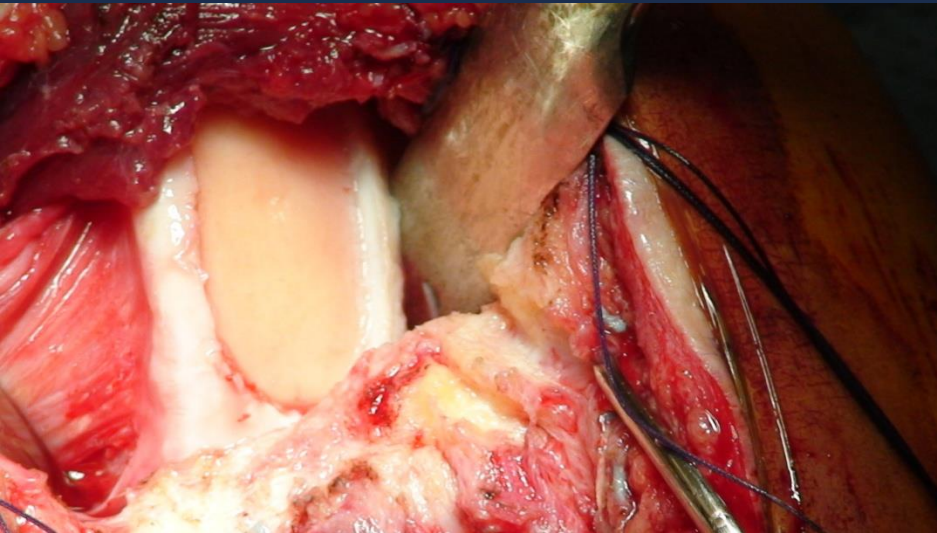
Stabilizer poorly contained region



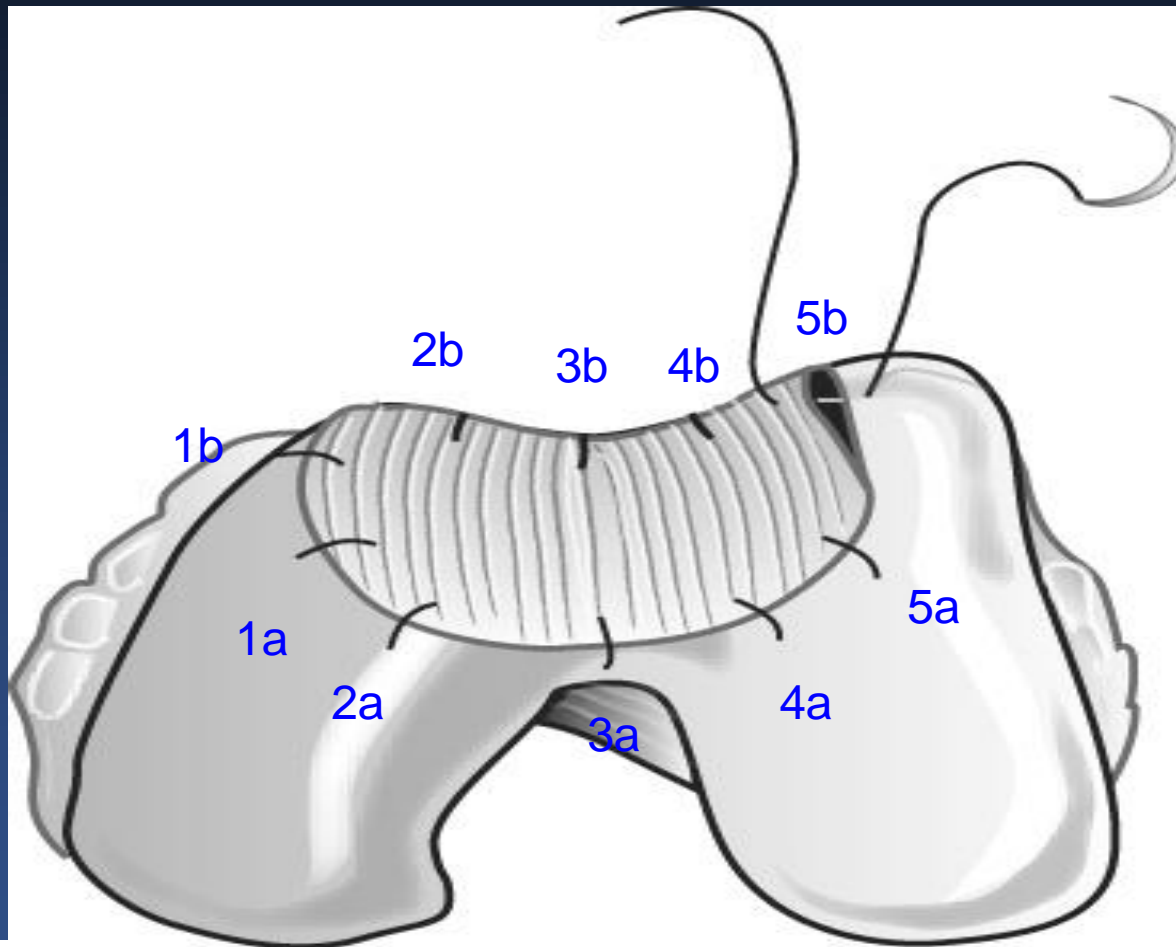
Poorly Contained Lesion – Micro-Fix Anchors



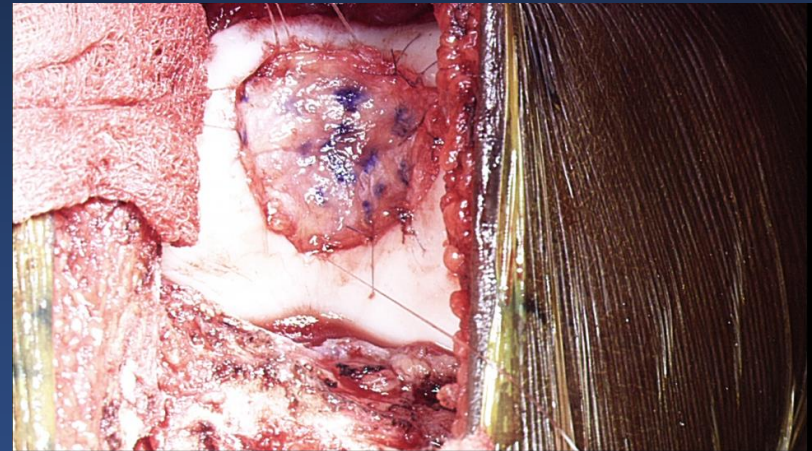
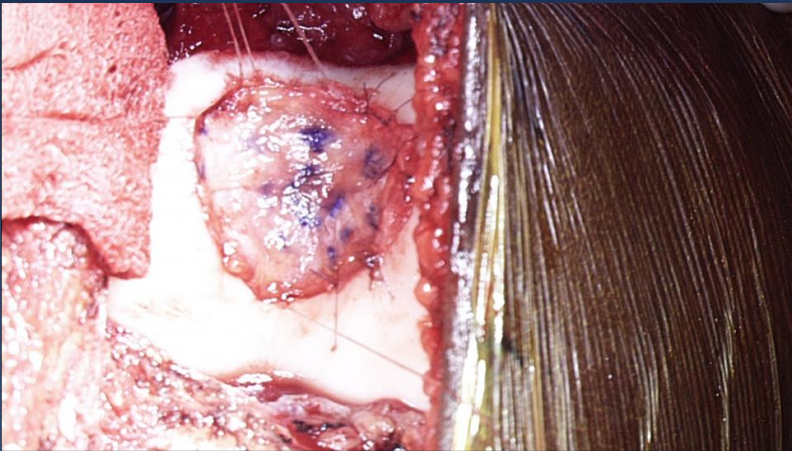
Large Lesion – limited fixation



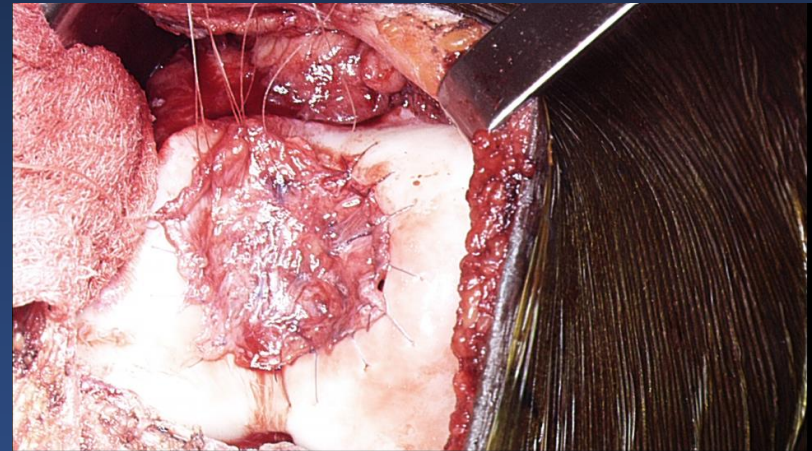
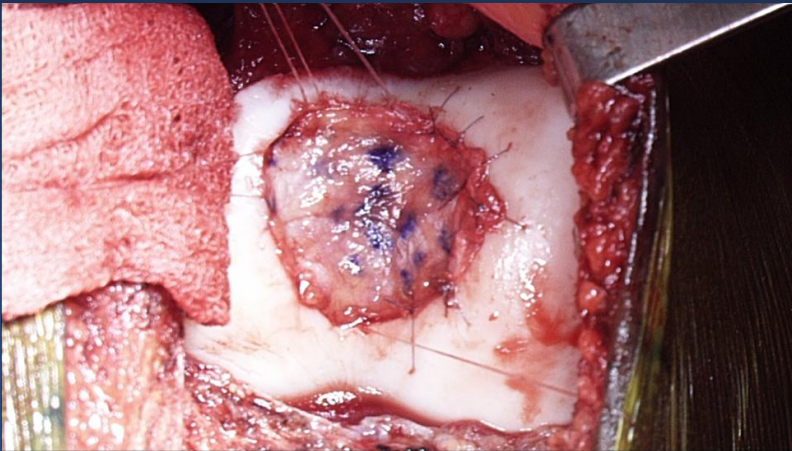
Trochlear Defects



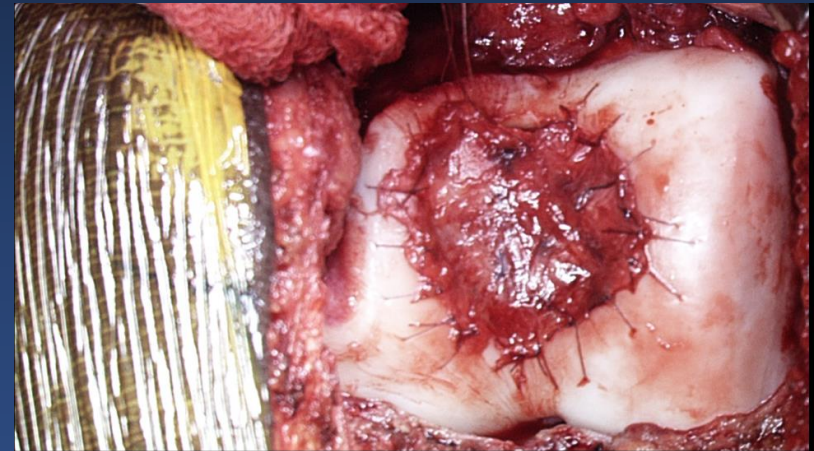
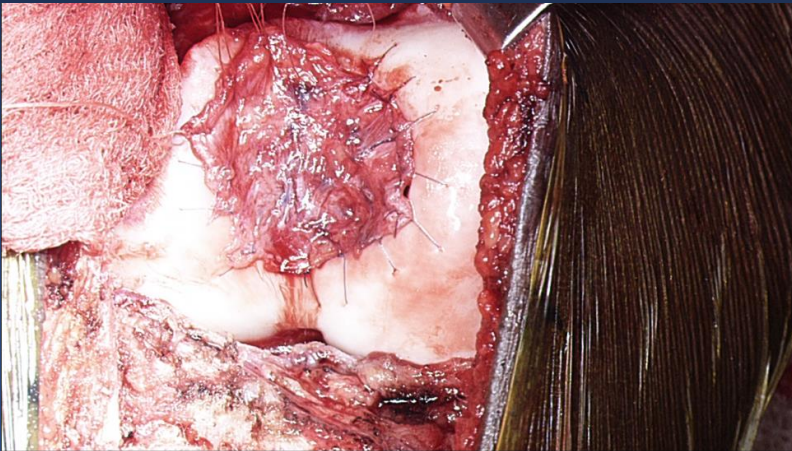
Suture fixation



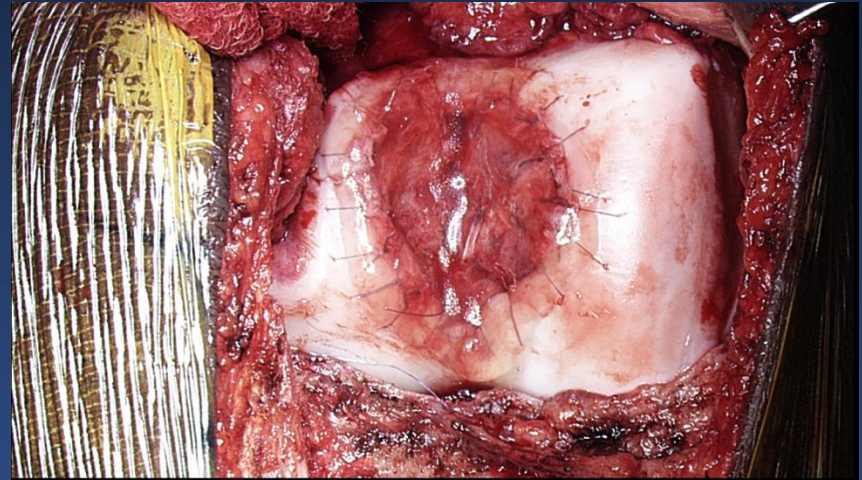
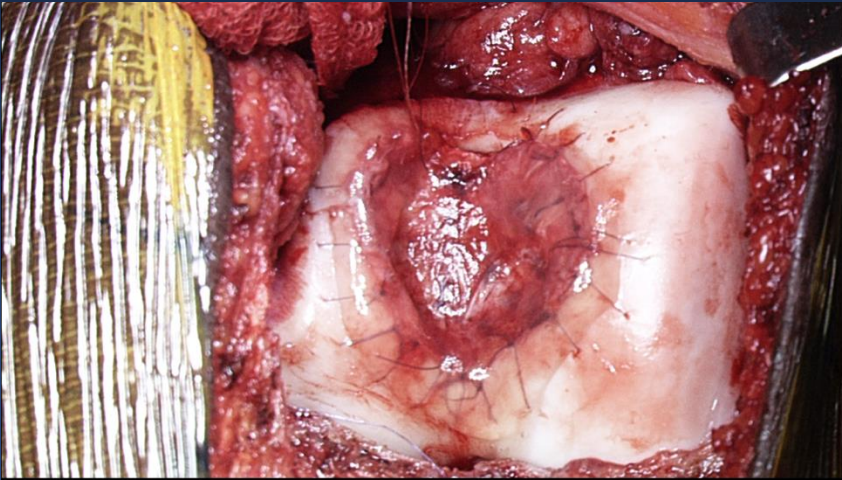
Graft placement



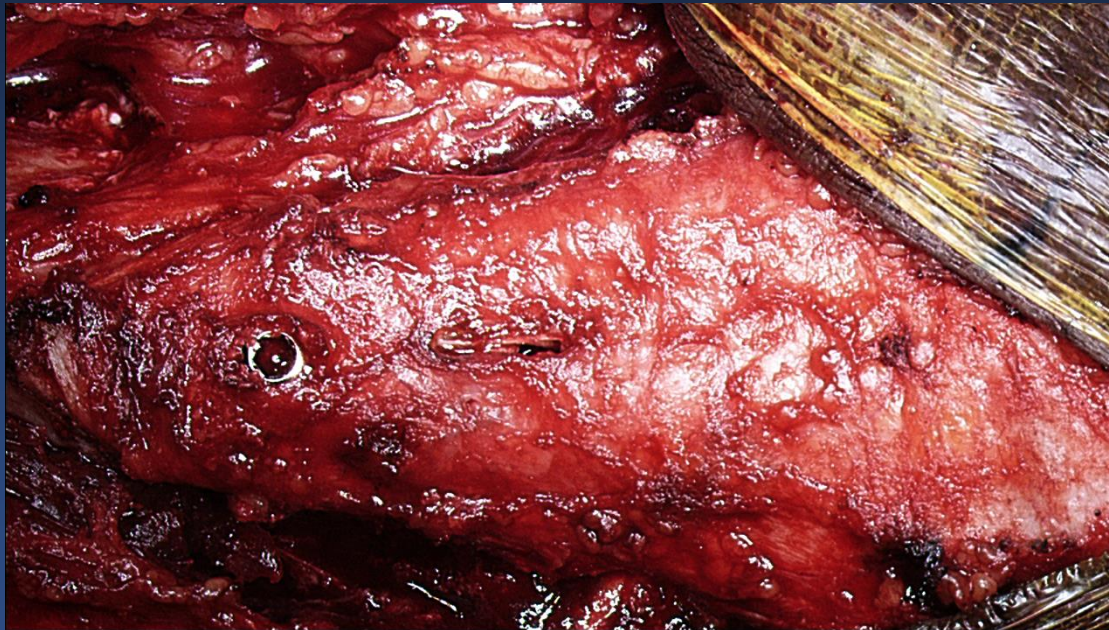
Graft Placement



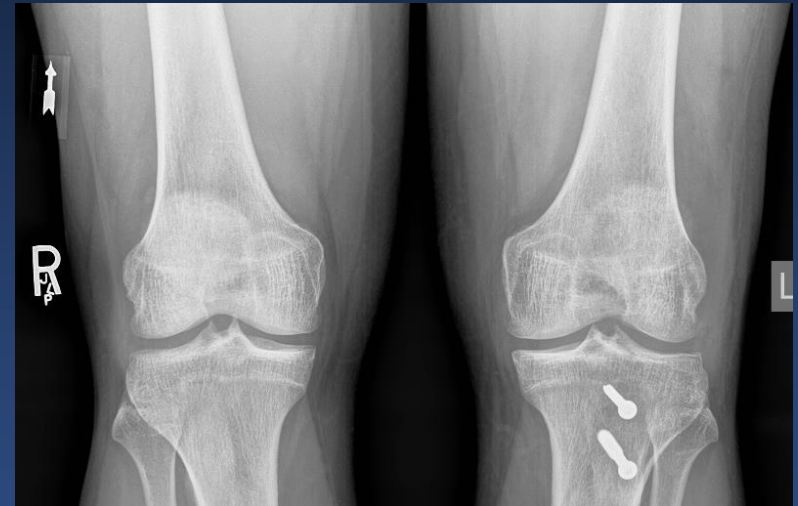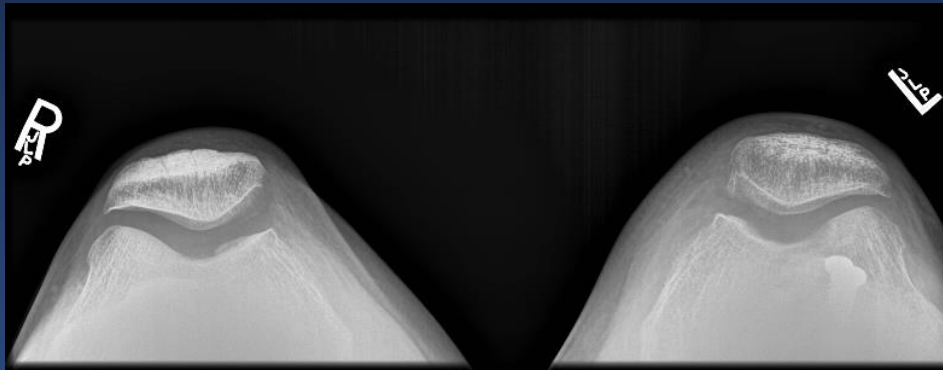
Implantation



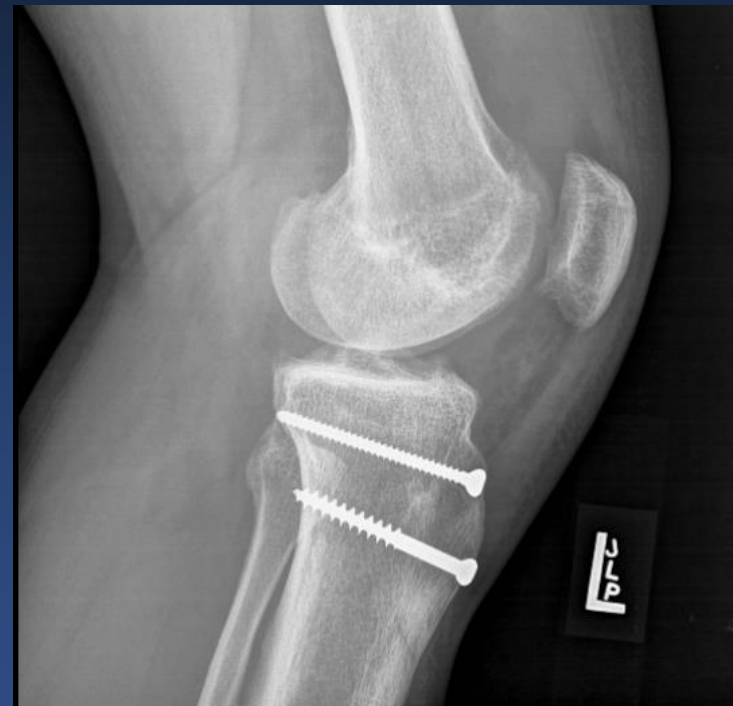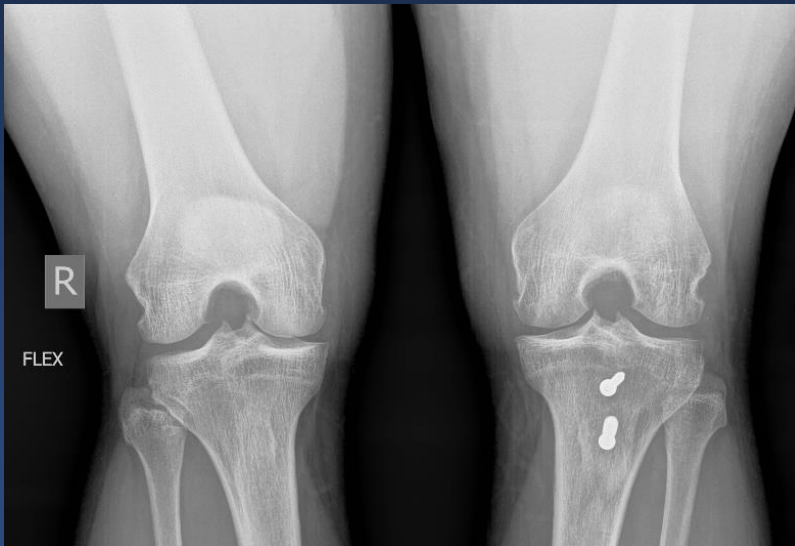Fixation Tubercleplasty



Postoperative Radiographs



Postoperative Radiographs



T2 Mapping and Cartilage Specific Sequences

