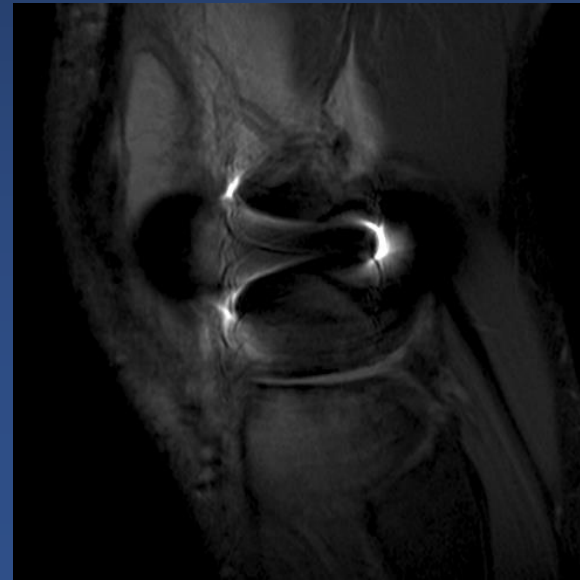
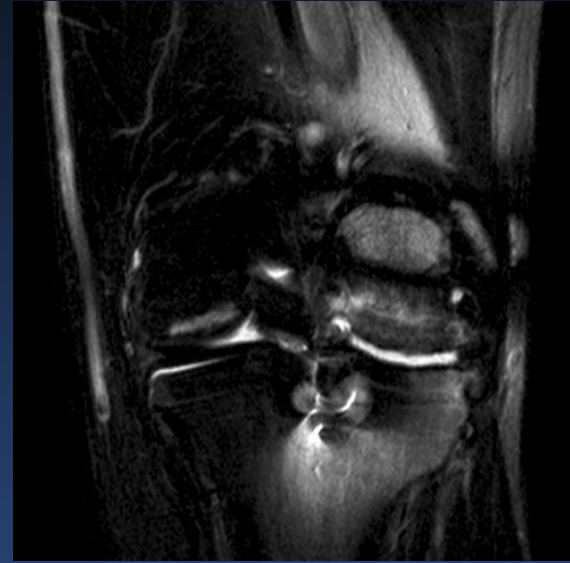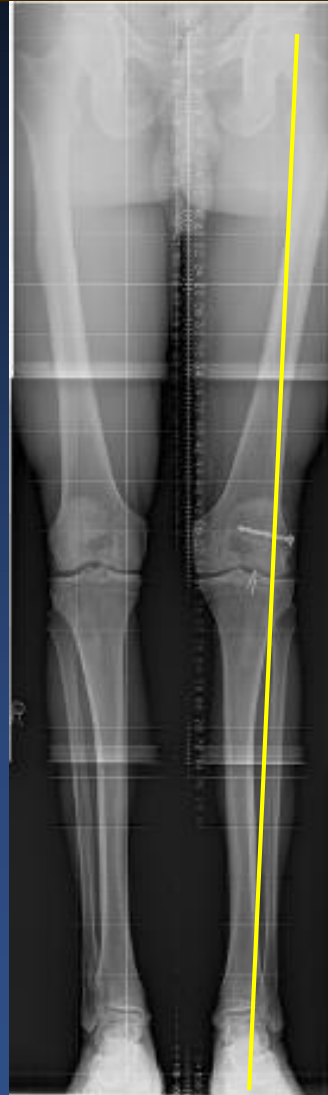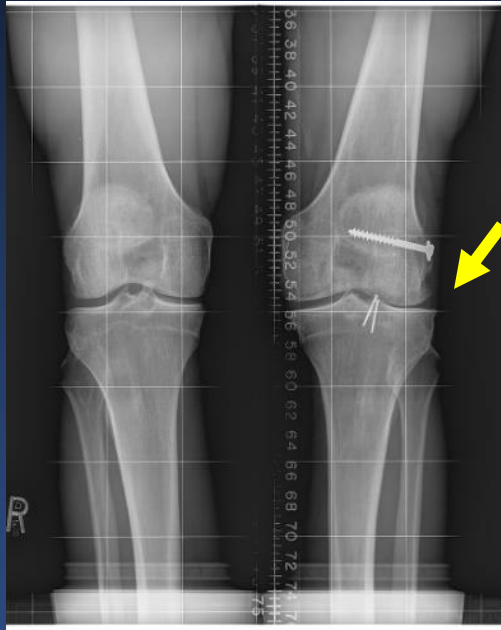


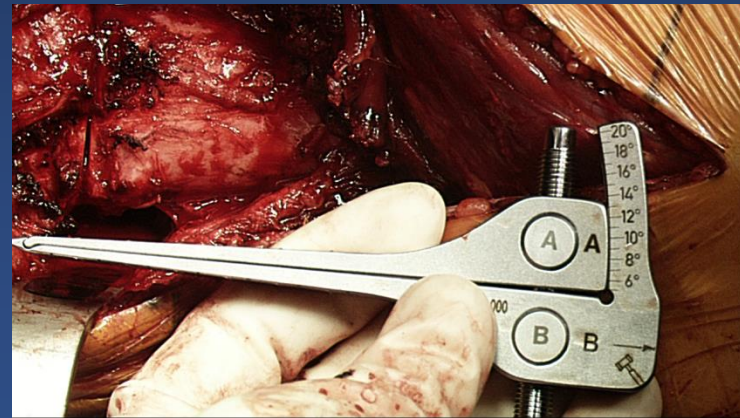
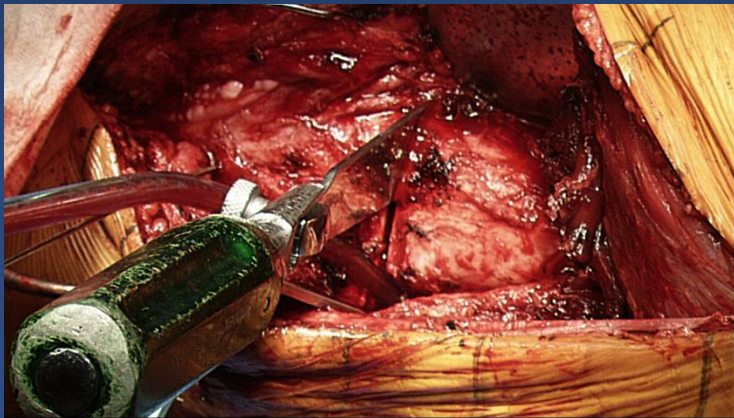
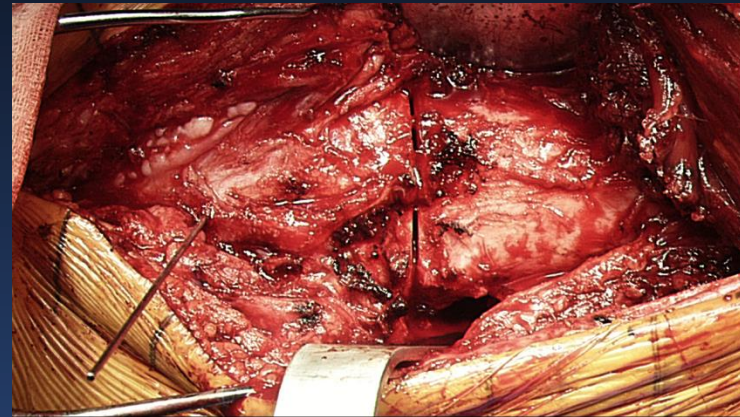
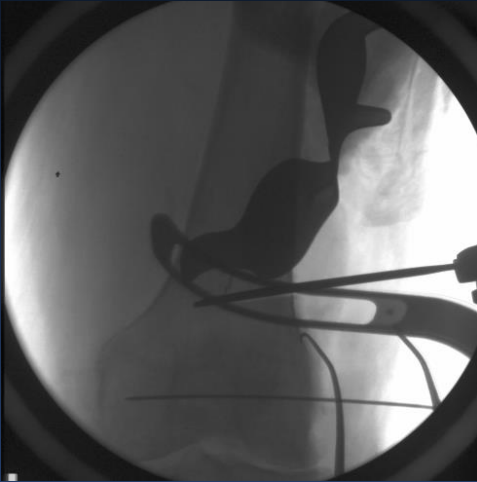
# Femoral Osteotomy Osteochondral Allograft Tibial Meniscal Transplant

Deryk Jones, MD  
Professor University of  
Queensland  
OSMI

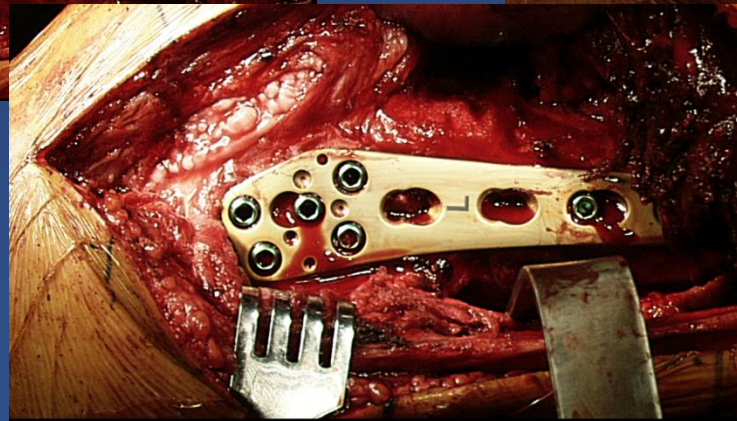
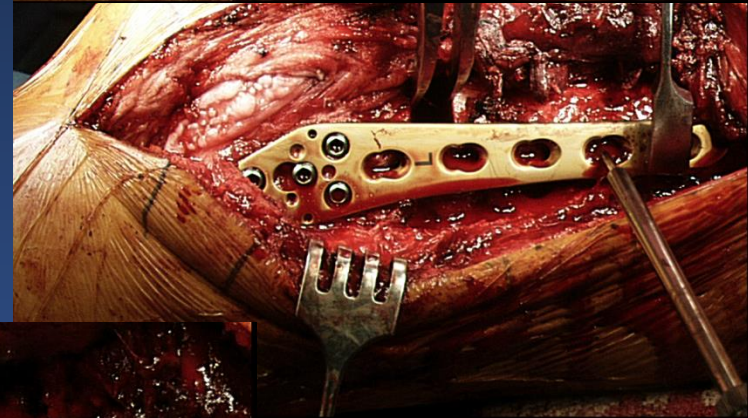
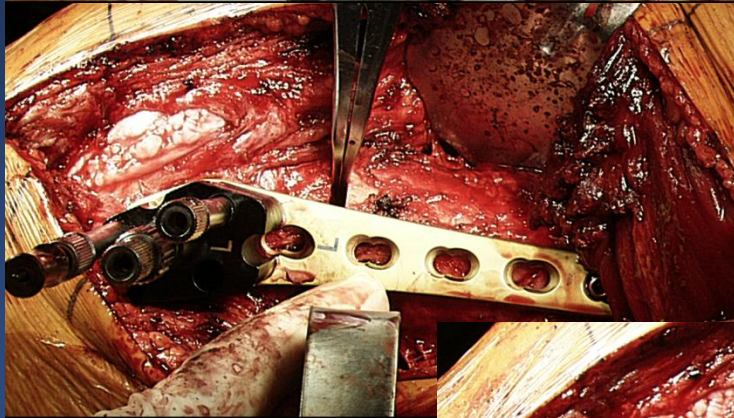
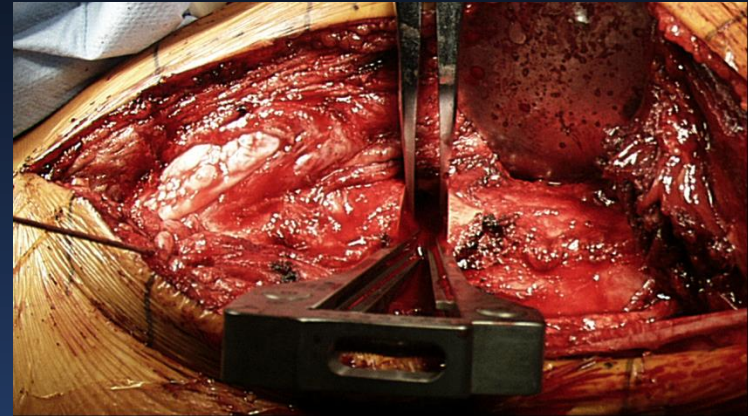
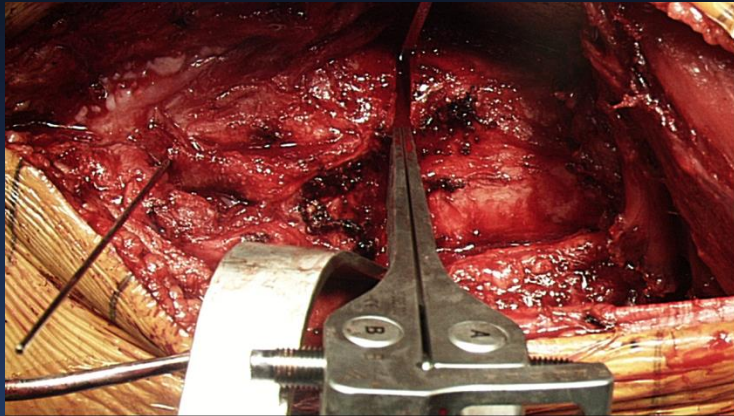
# Preoperative Studies



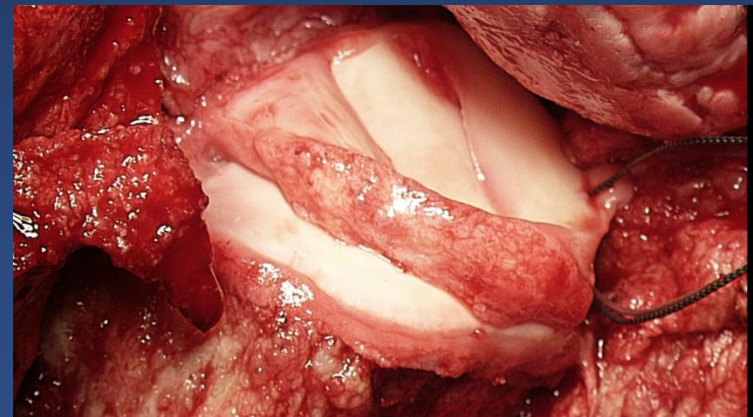
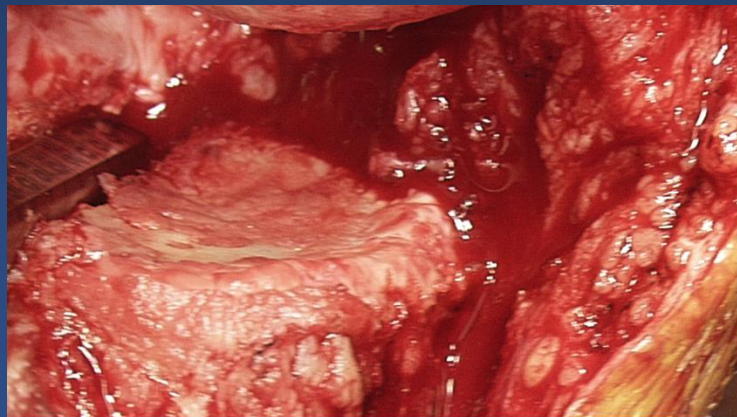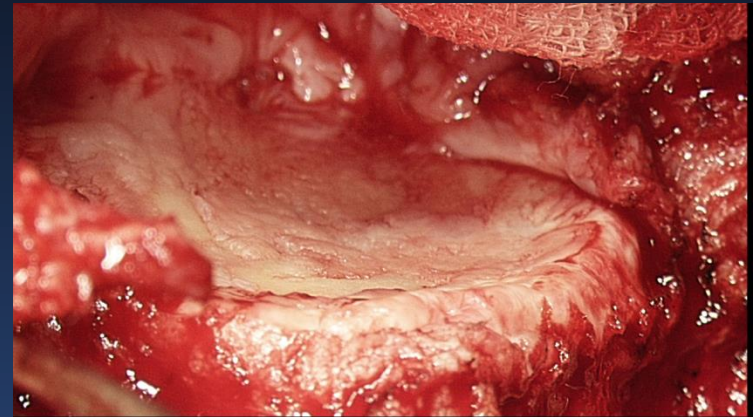
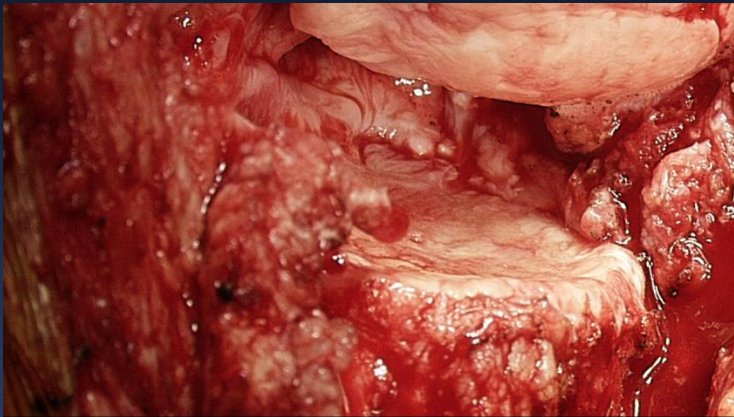
# DFO: Osteochondral and Meniscal Allograft Case



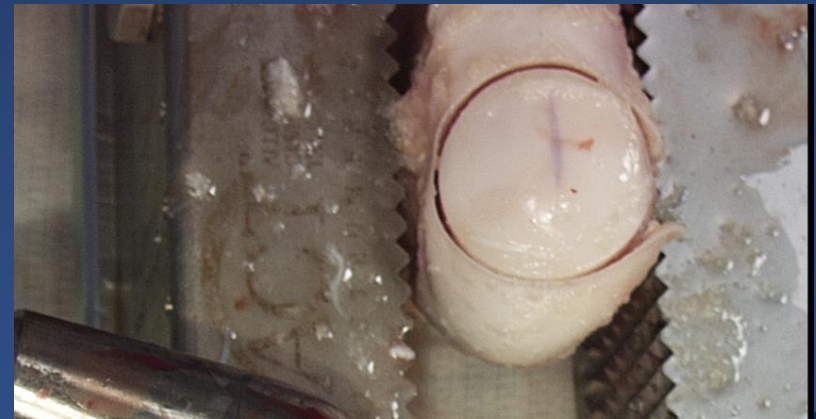
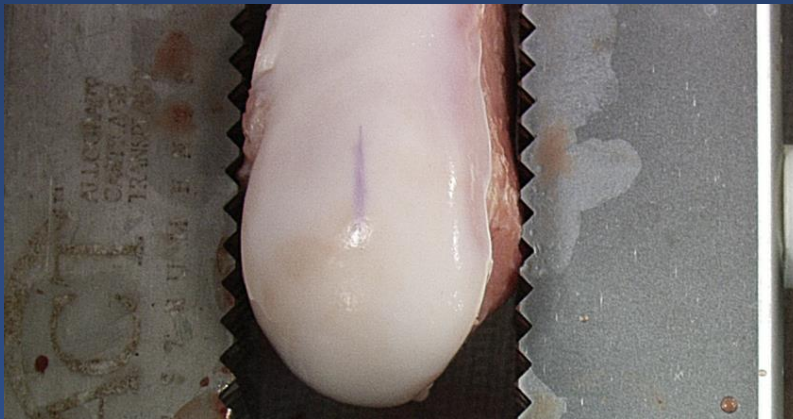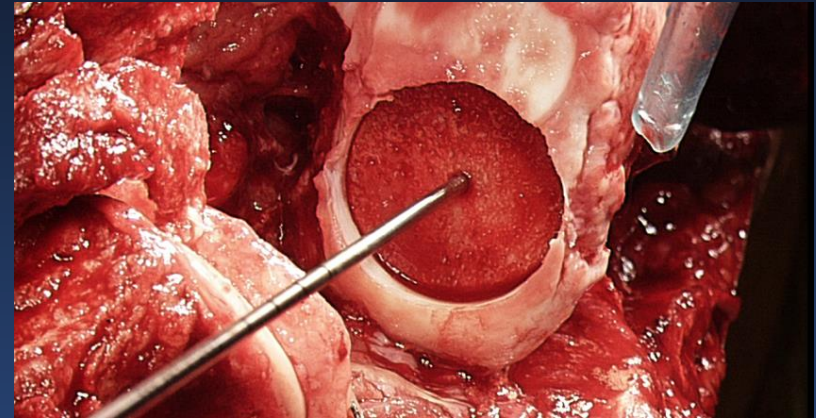
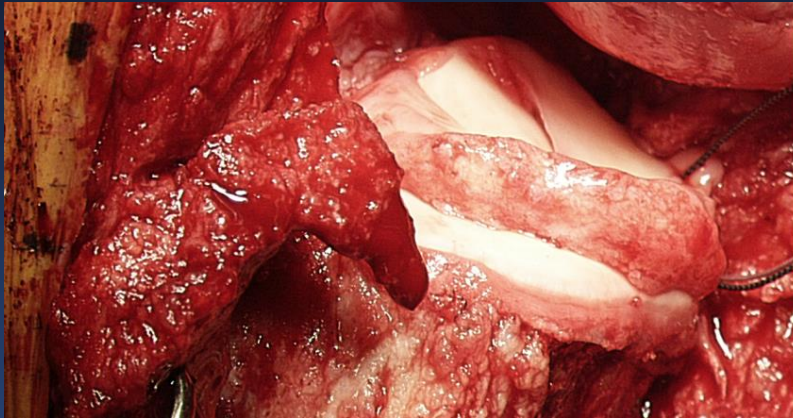
# Open Osteotomy Jack / Laminar Spreader with Plate Fixation



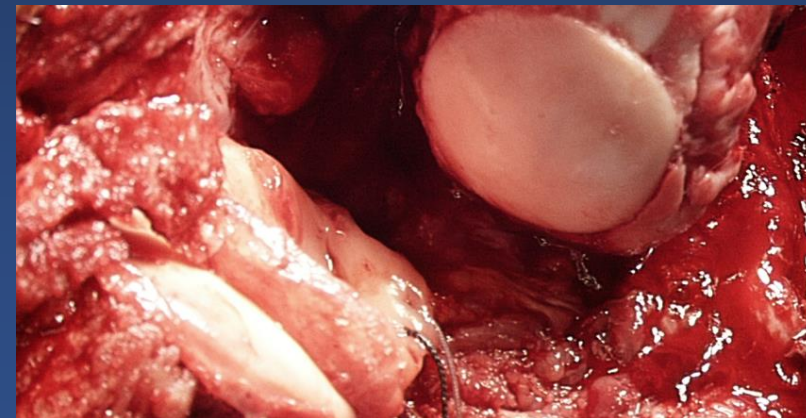
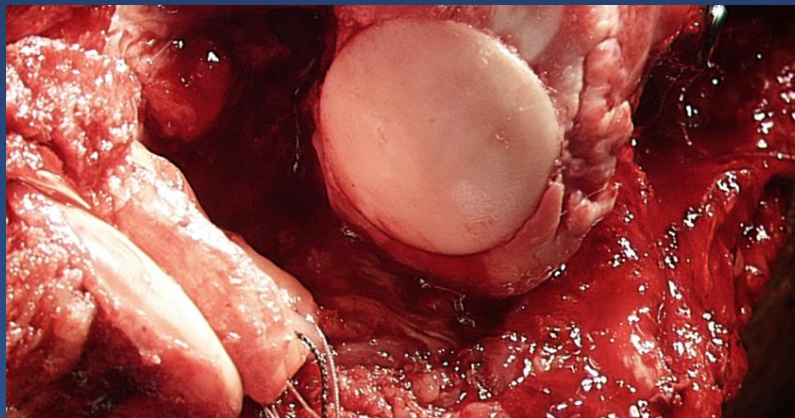
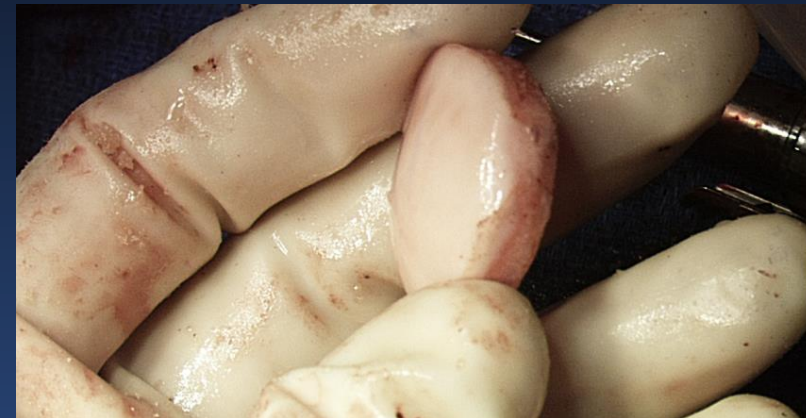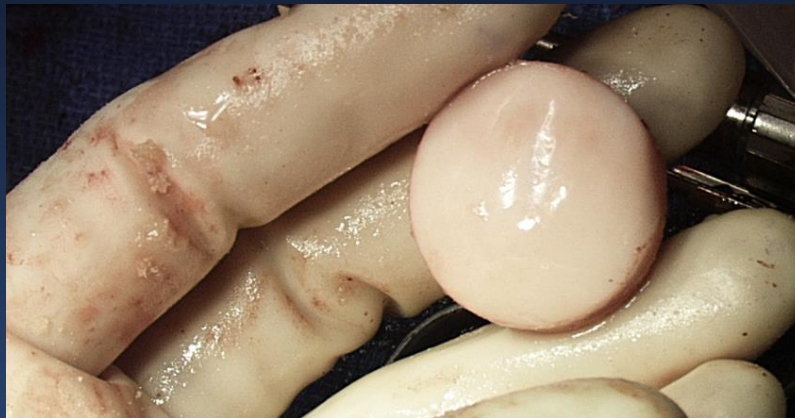# Tibial Surface: Slot Preparation and Tibial-Meniscal Allograft



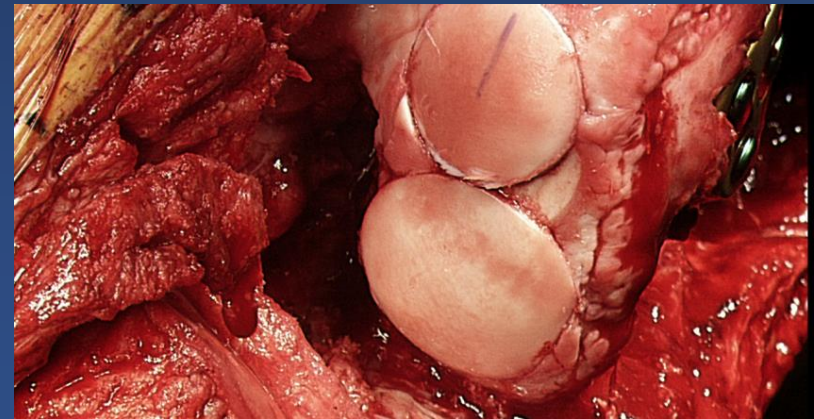
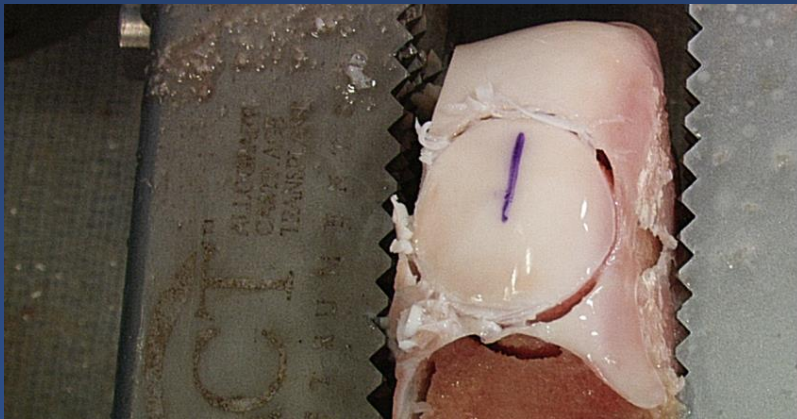
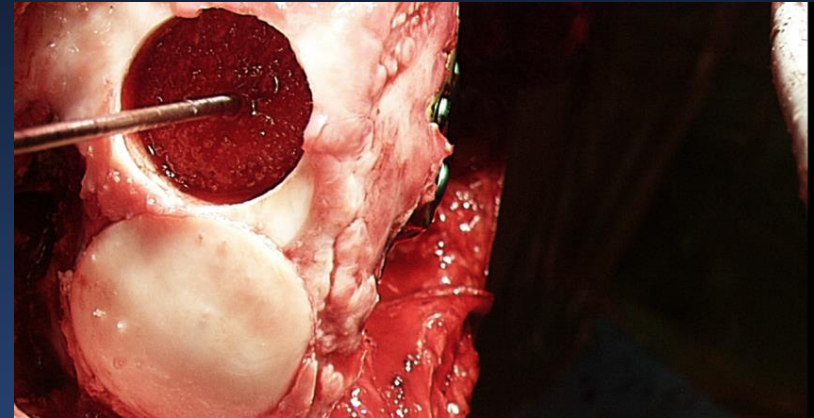
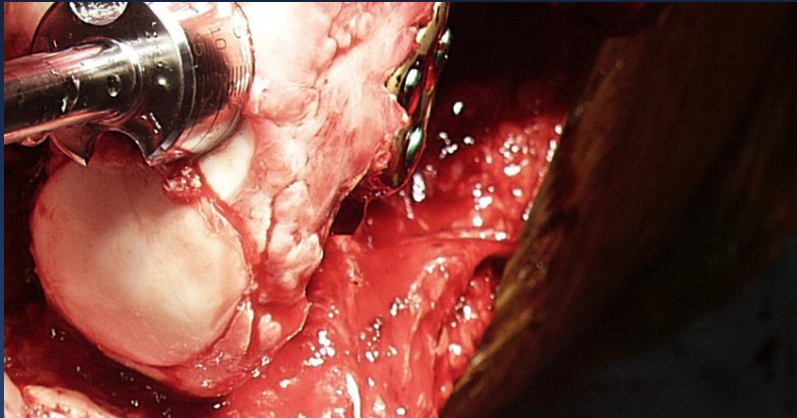# Osteochondral Allograft Preparation



# Minimize Bone Load (8-10mm)

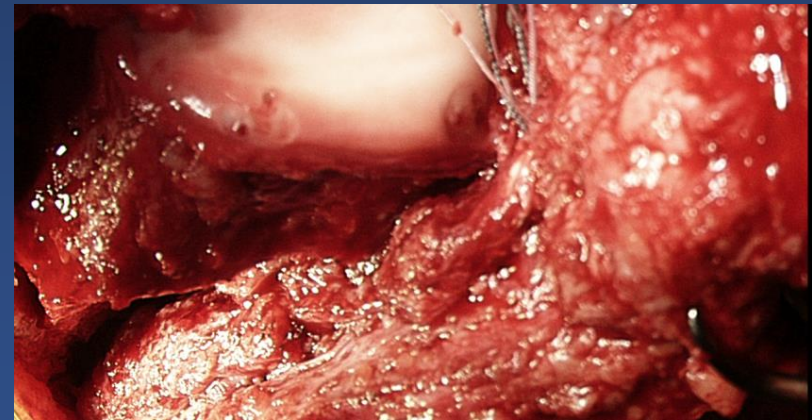
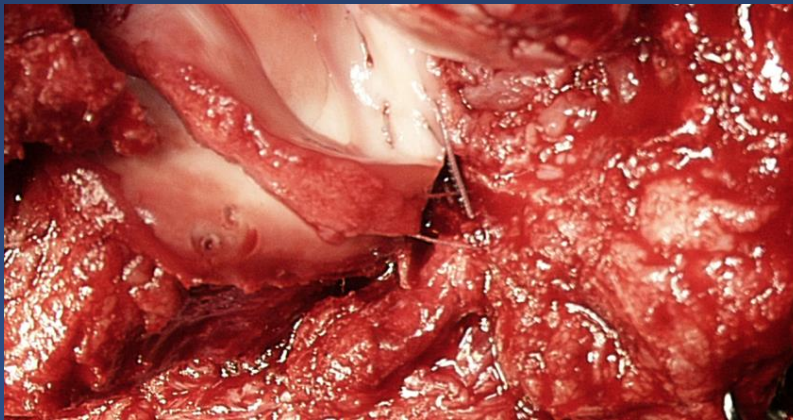
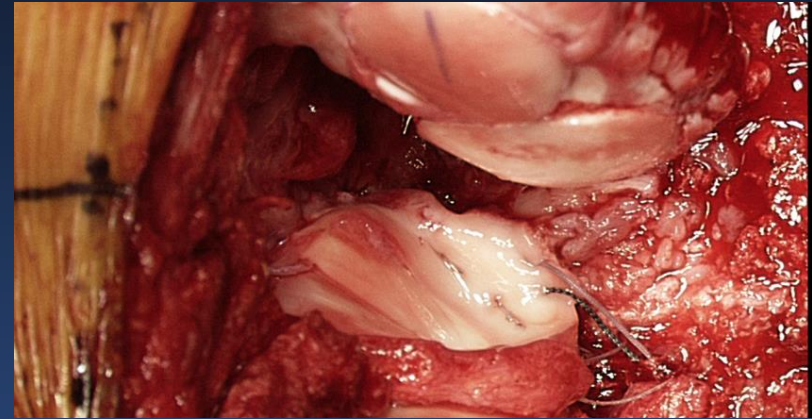
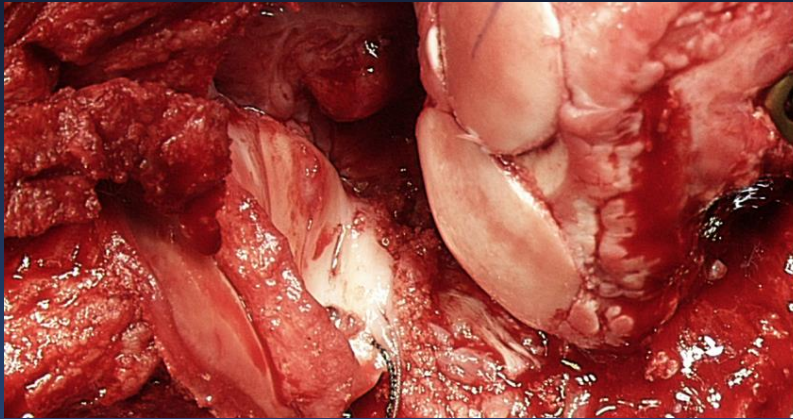


# Osteochondral Allograft Snowman

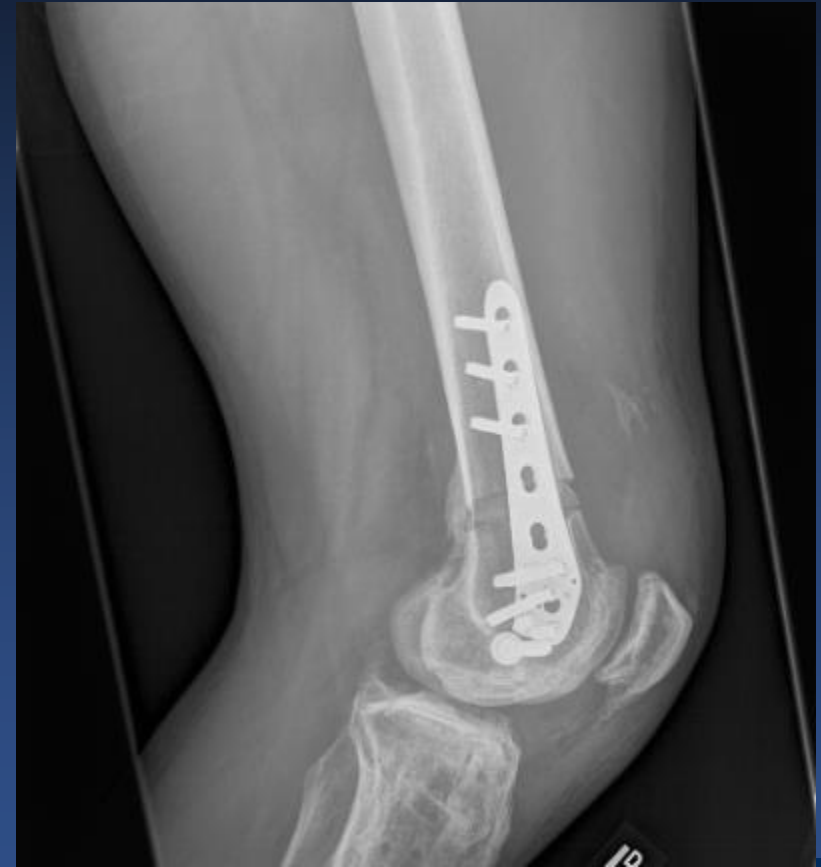
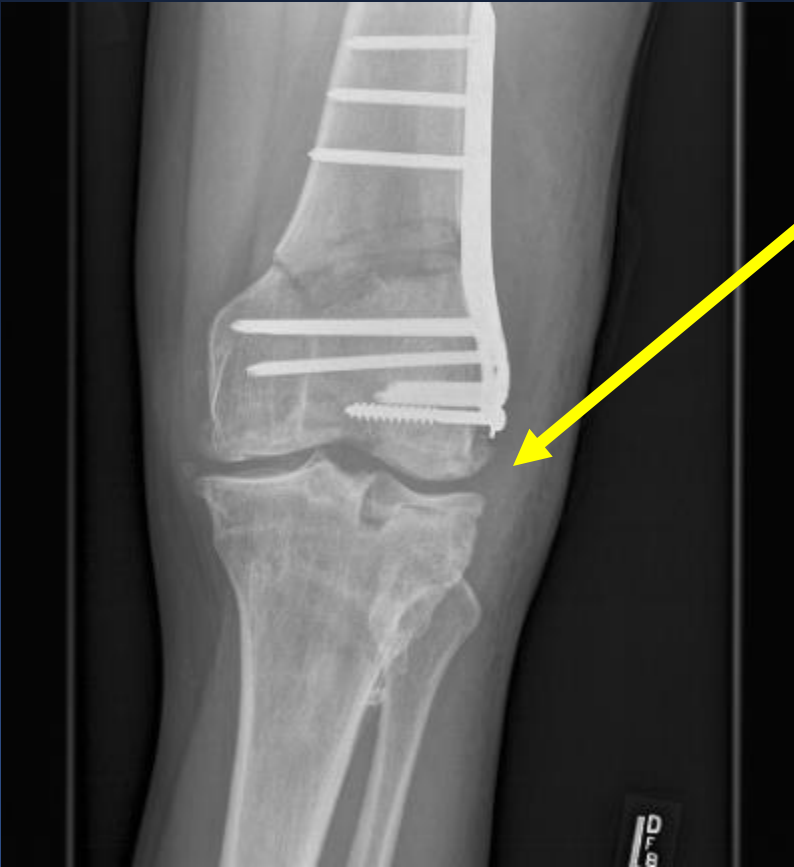


# Meniscal Graft Suturing



# Postoperative Radiograph



# Second Look Arthroscopy

Medial Compartment

Lateral Compartment

