

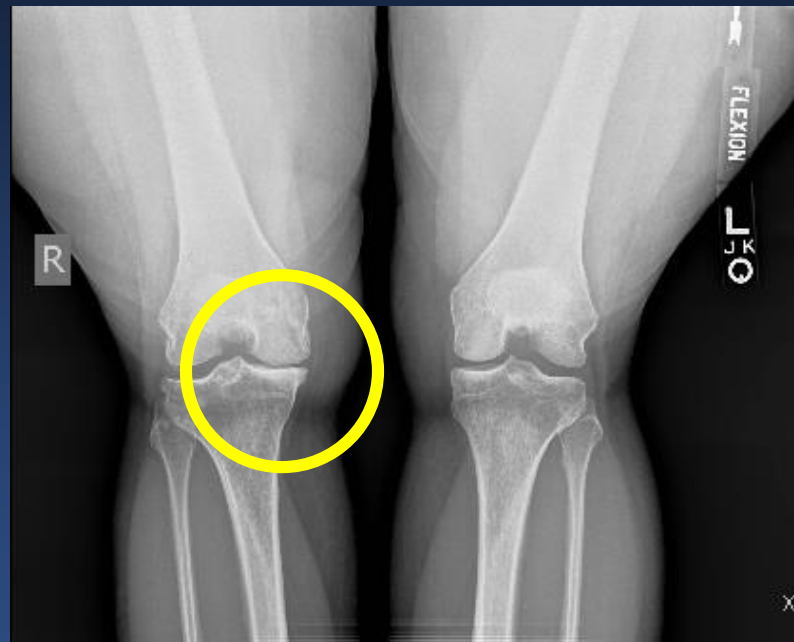
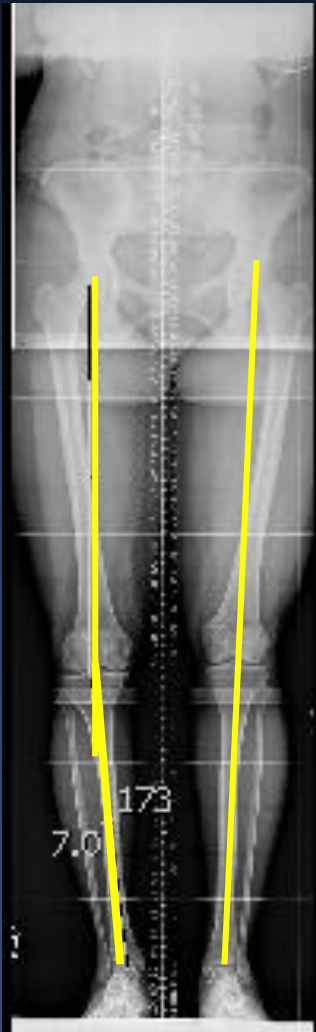


# Anterior Cruciate Ligament and High Tibial Osteotomy Case

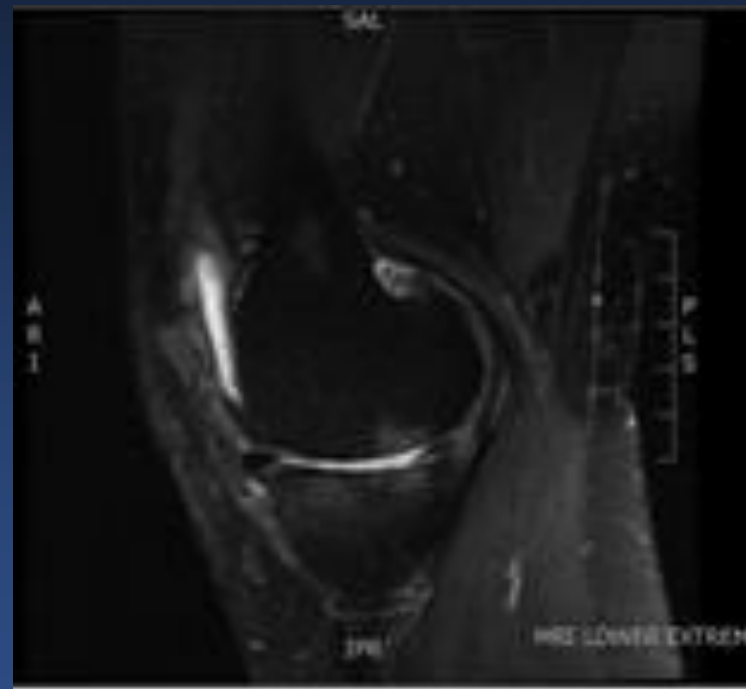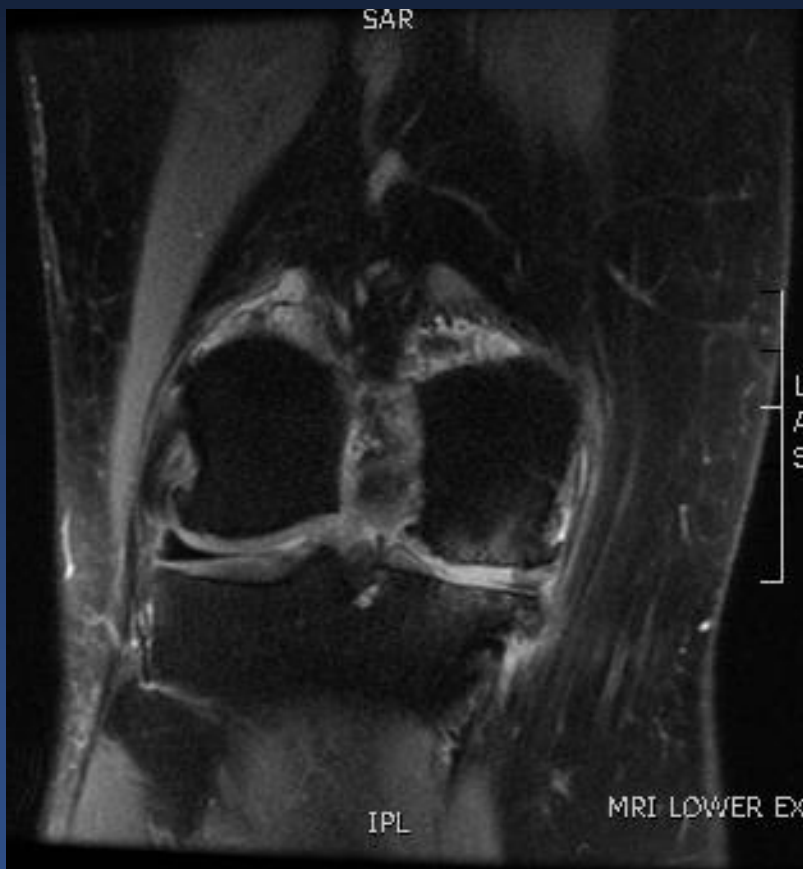
Deryk Jones, MD  
Professor University of  
Queensland  
OSMI



# Preoperative Radiographs

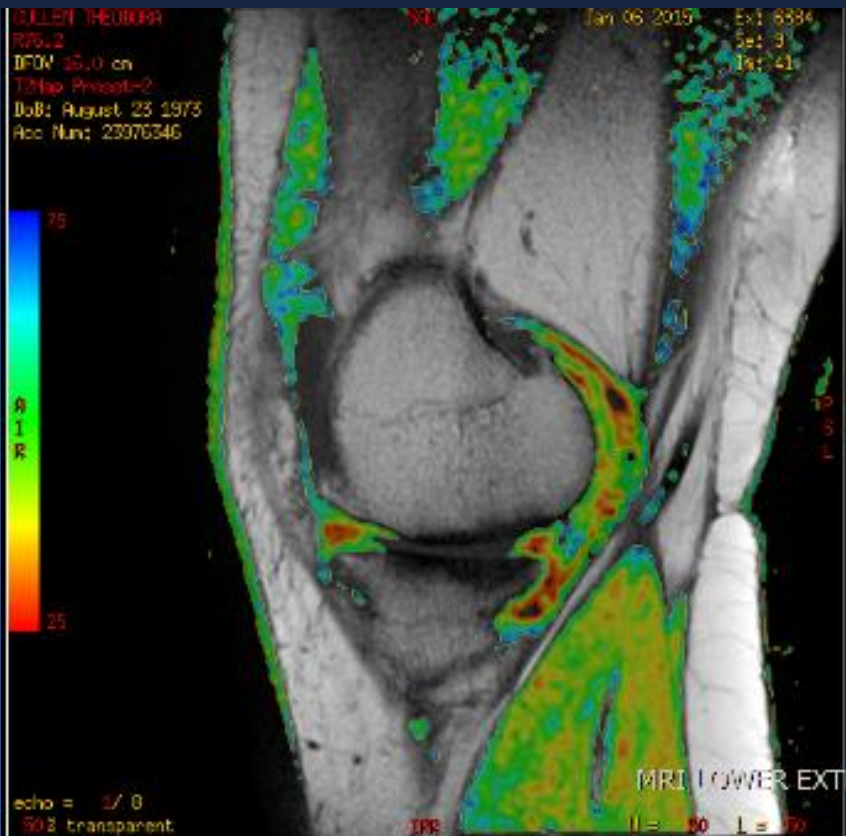


# Medial ICRS Grade 4 Kissing Lesions

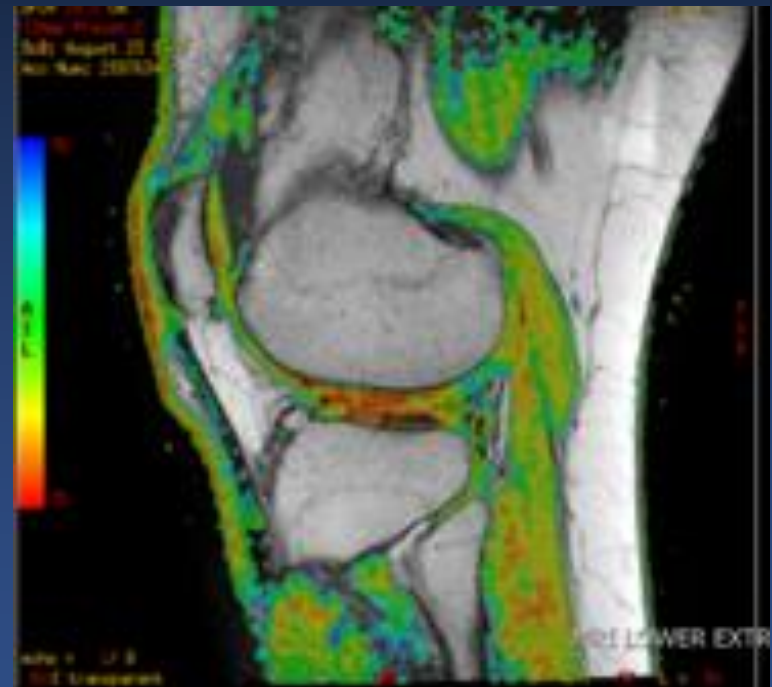


# T2 Mapping Preoperative Images

## Medial Compartment

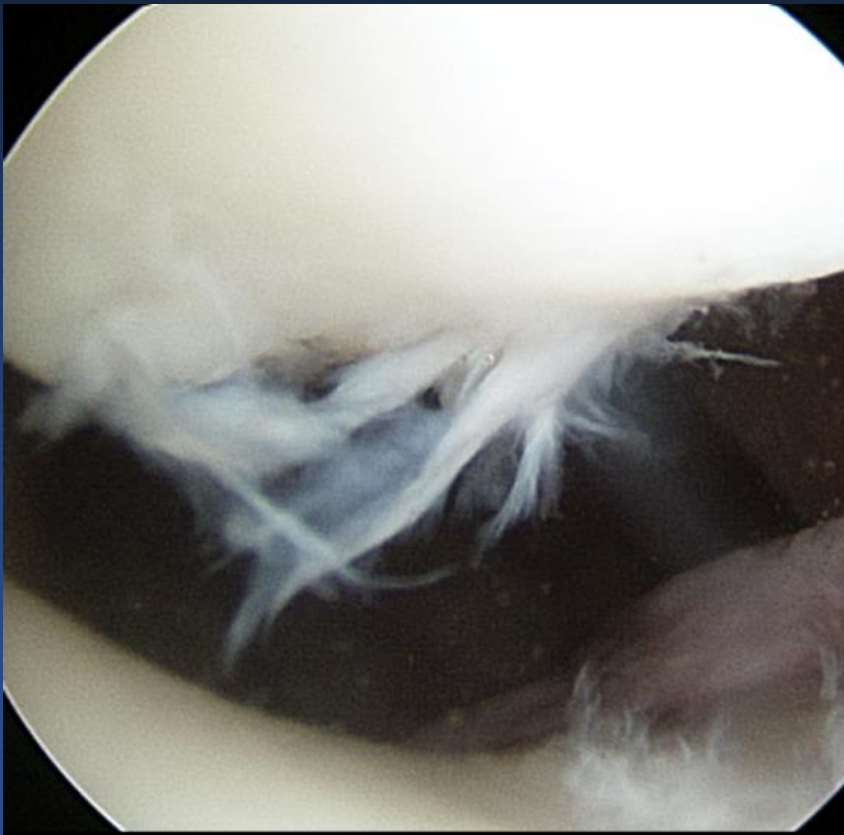


## Lateral Compartment

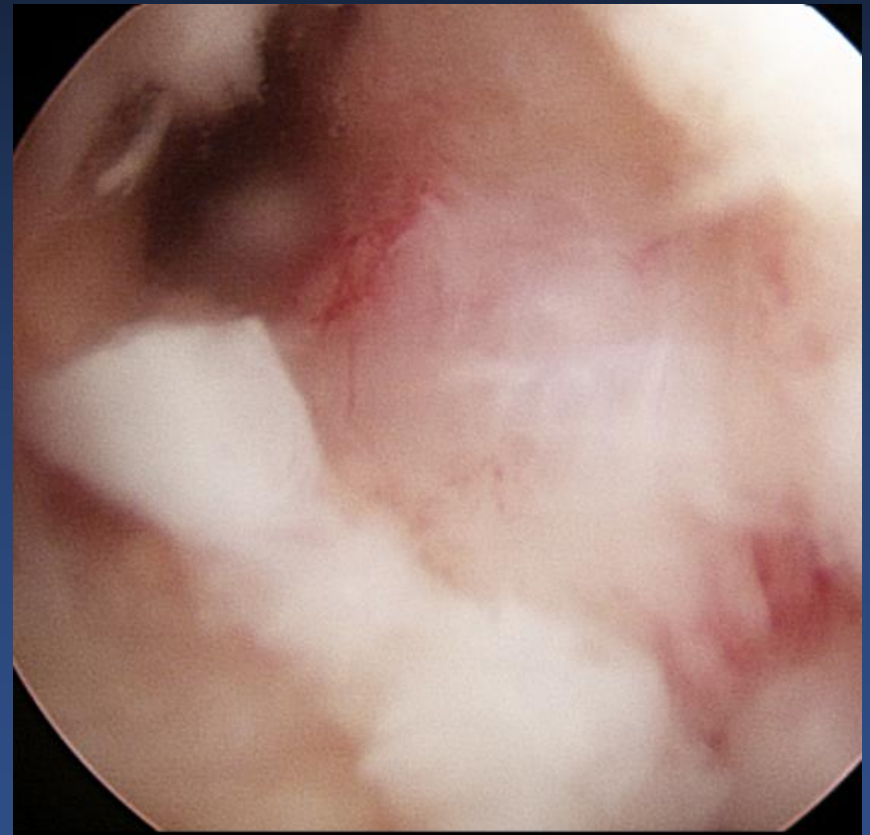

# Arthroscopic Pictures

## Patellofemoral Joint

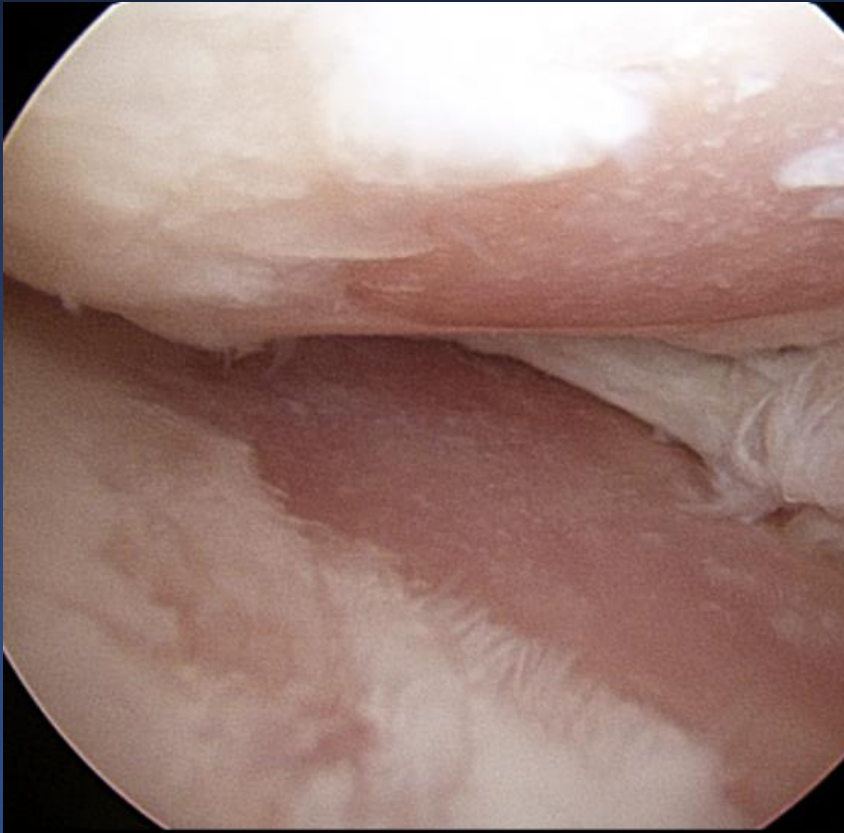


## Chronic ACL Tear

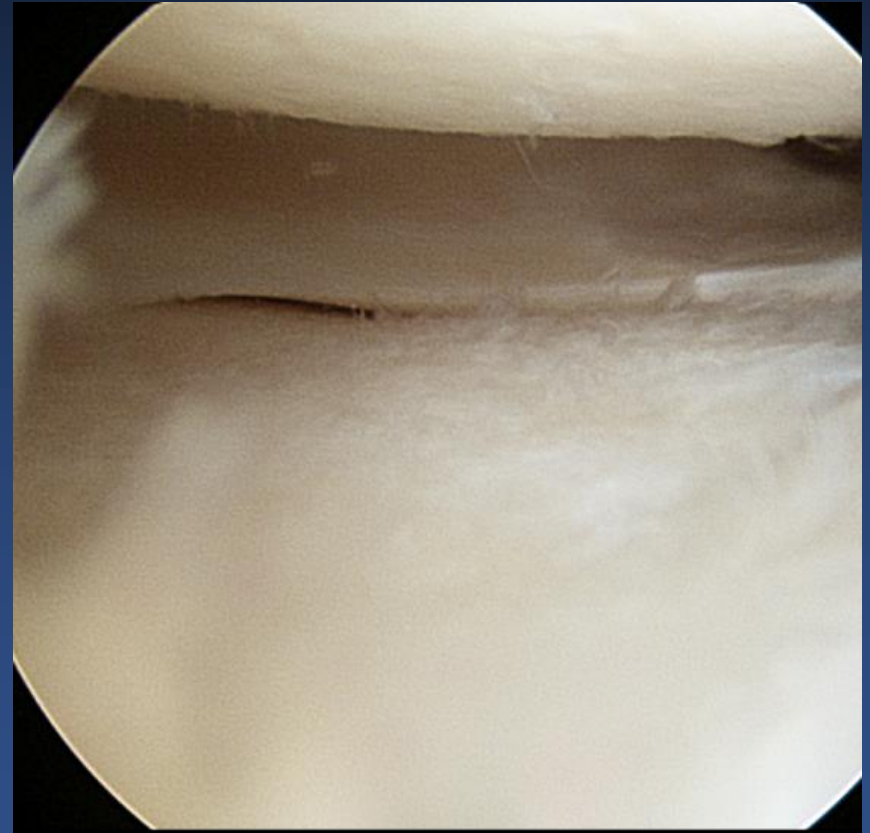


# Arthroscopic Pictures

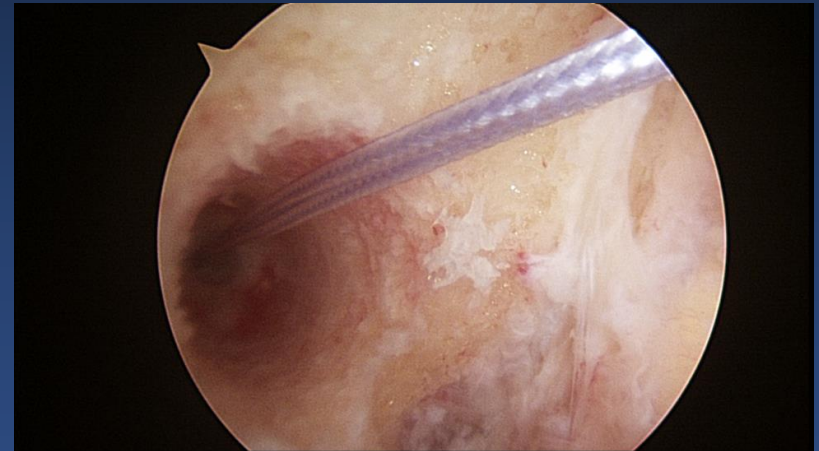
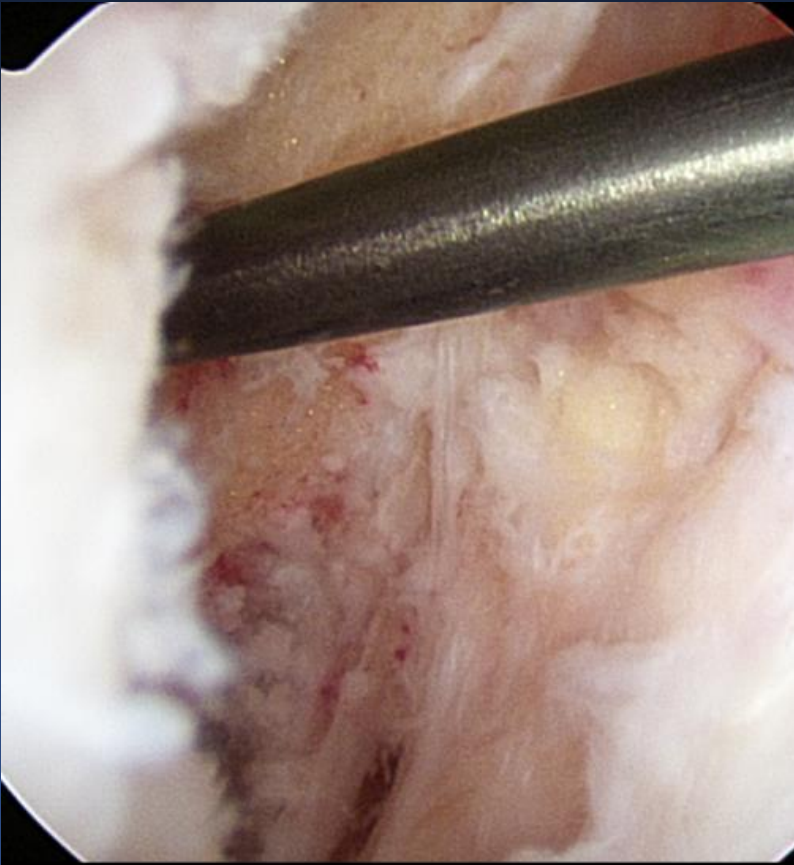
Medial Compartment Grade  
4 lesions



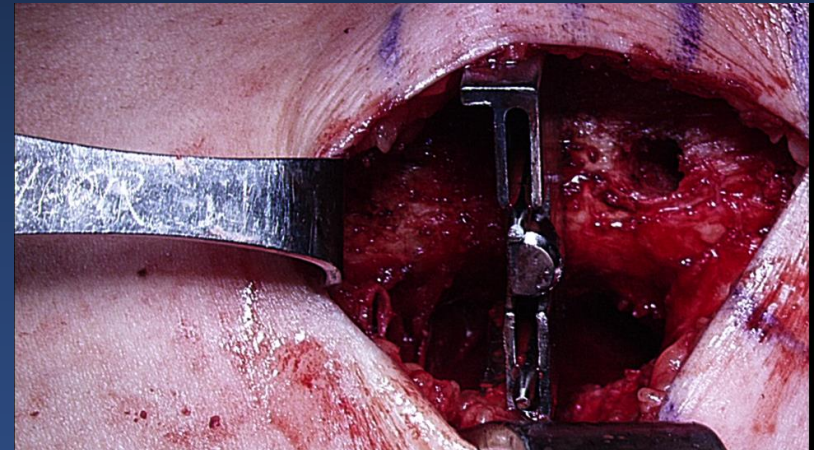
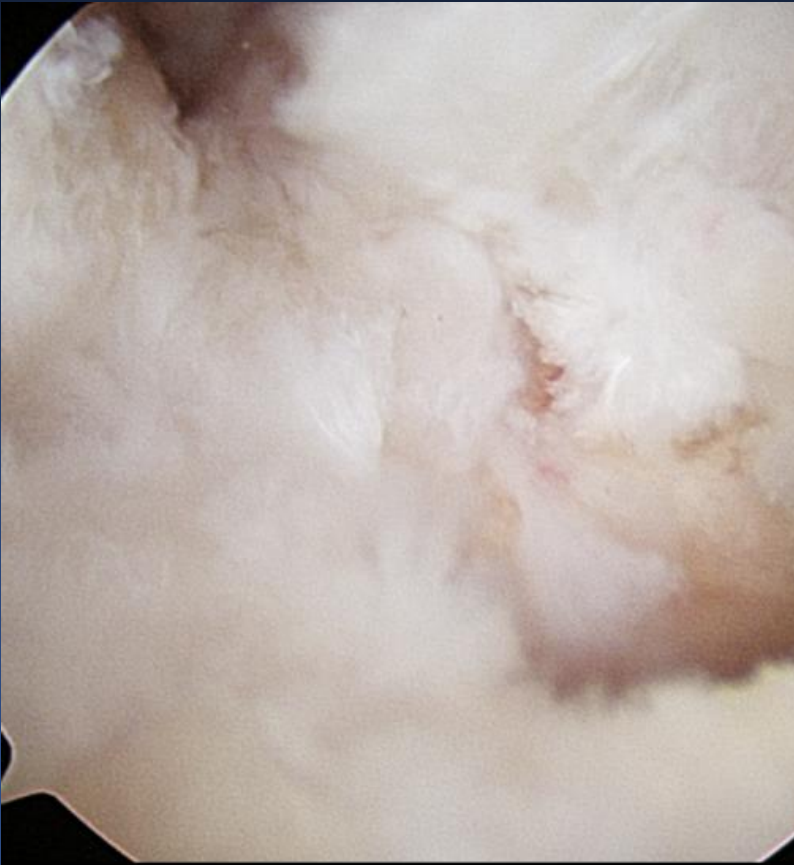
Lateral Compartment



# Single Femoral Tunnel

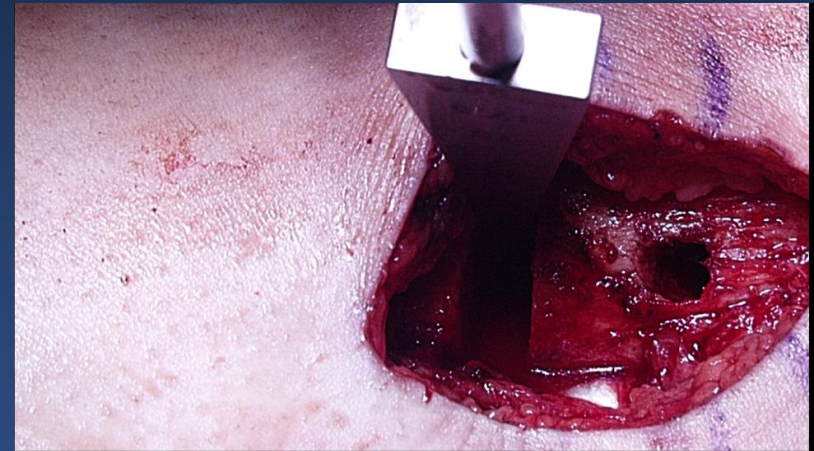
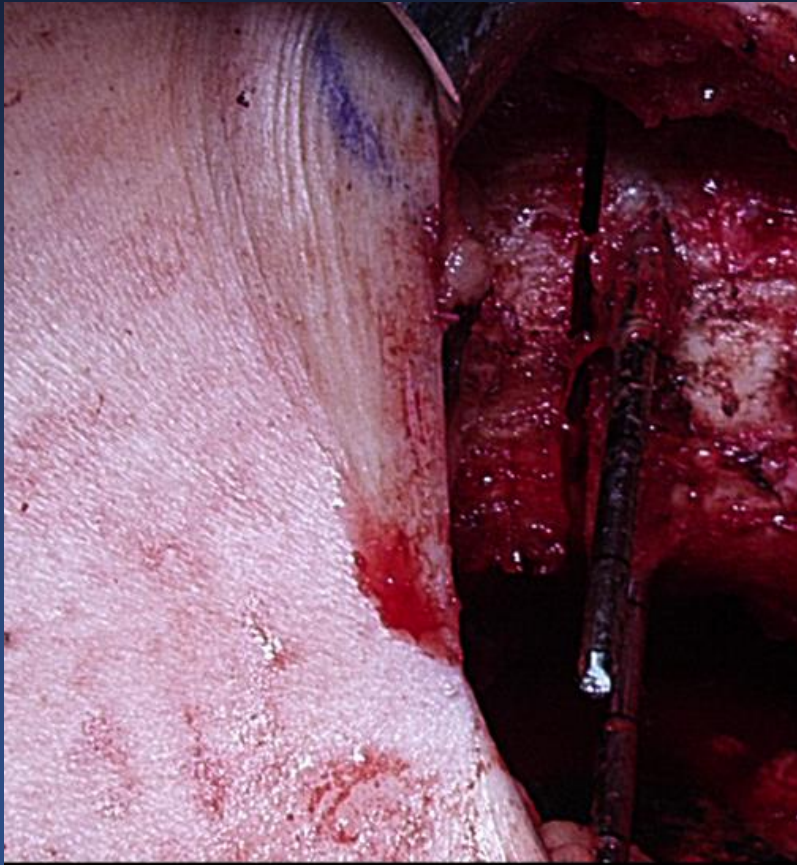


# Single Tibial Tunnel

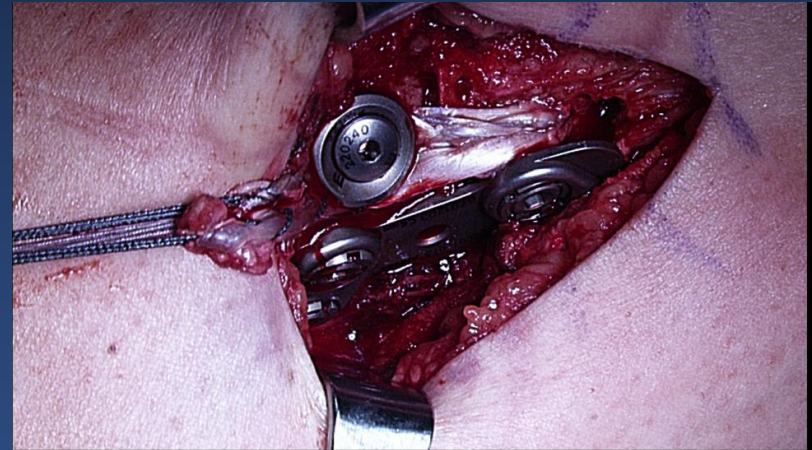
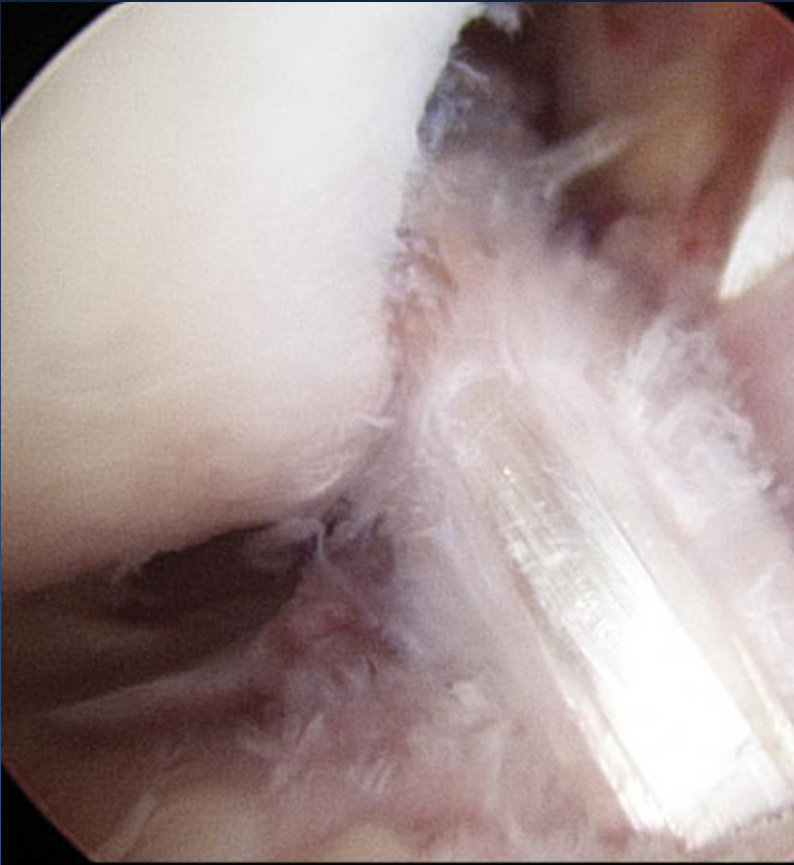




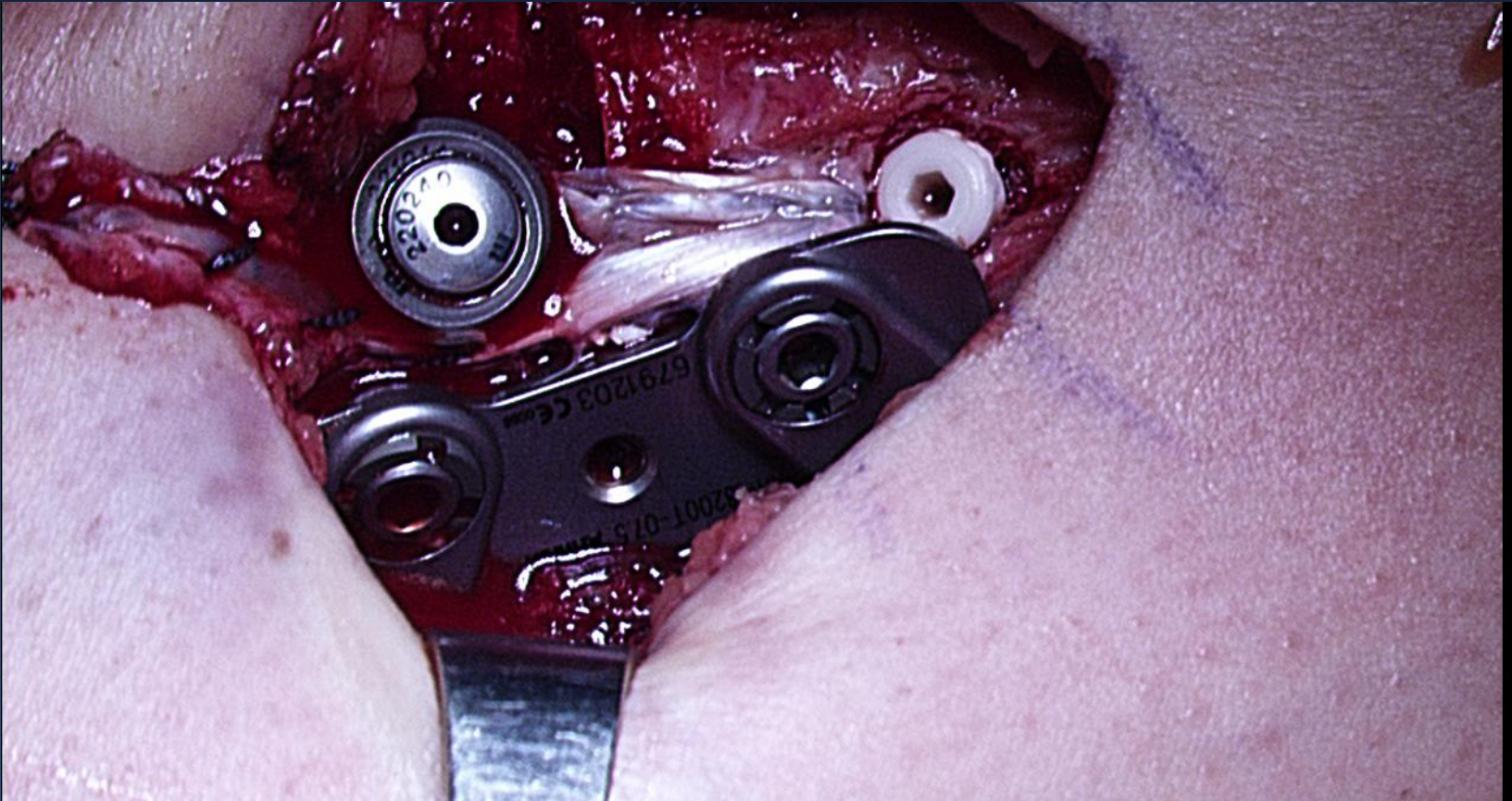
# Osteotomy below Tibial Tunnel



# Quadrupled ACL Autologous Graft



# Distal Fixation with Puddu Plate



# Postoperative Image - Lateral

